

Physical Diagnosis Potpourri

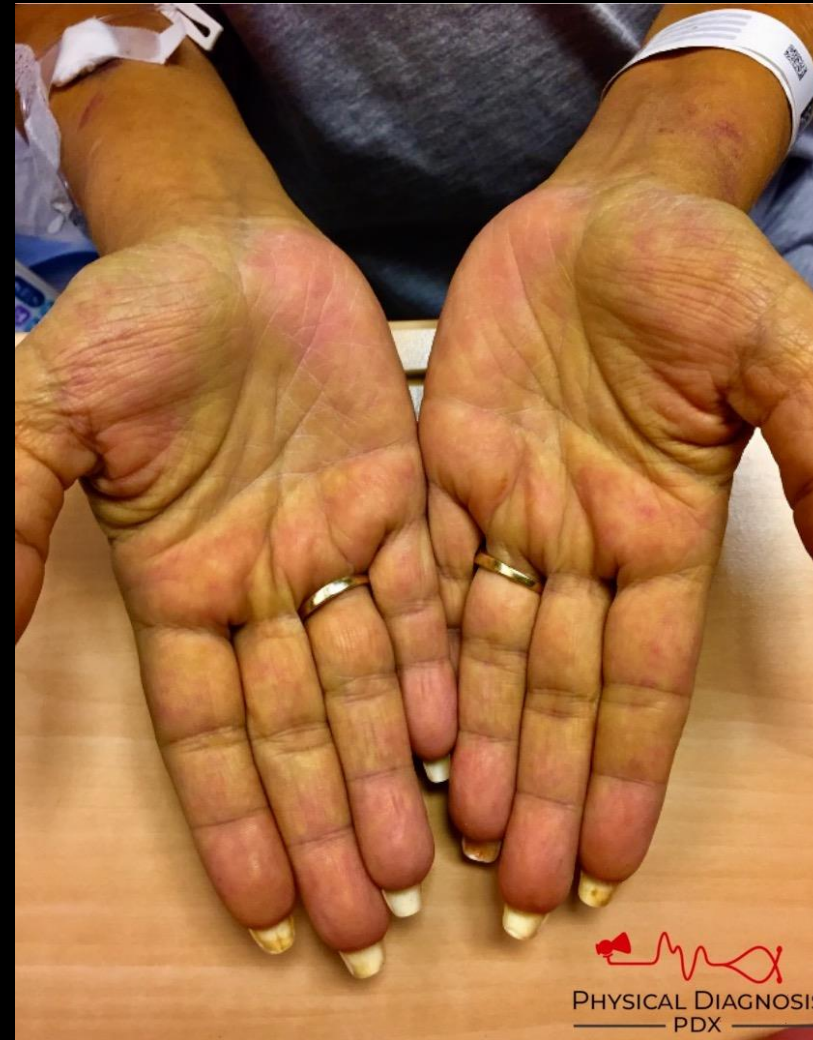
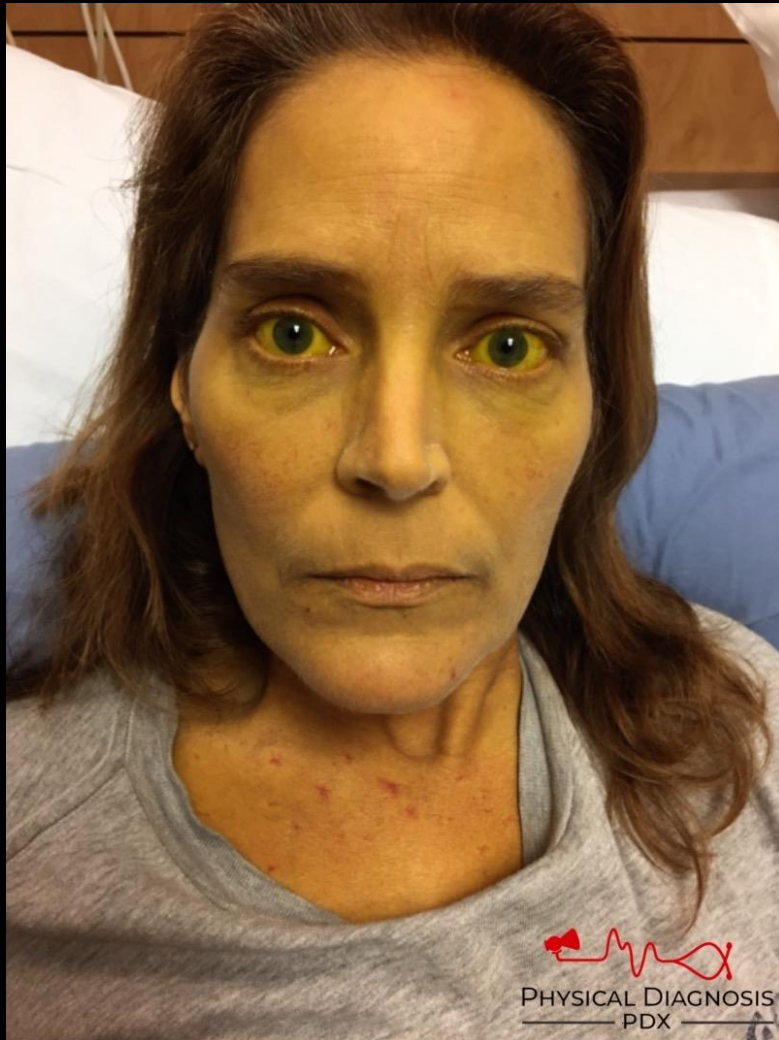
André M. Mansoor

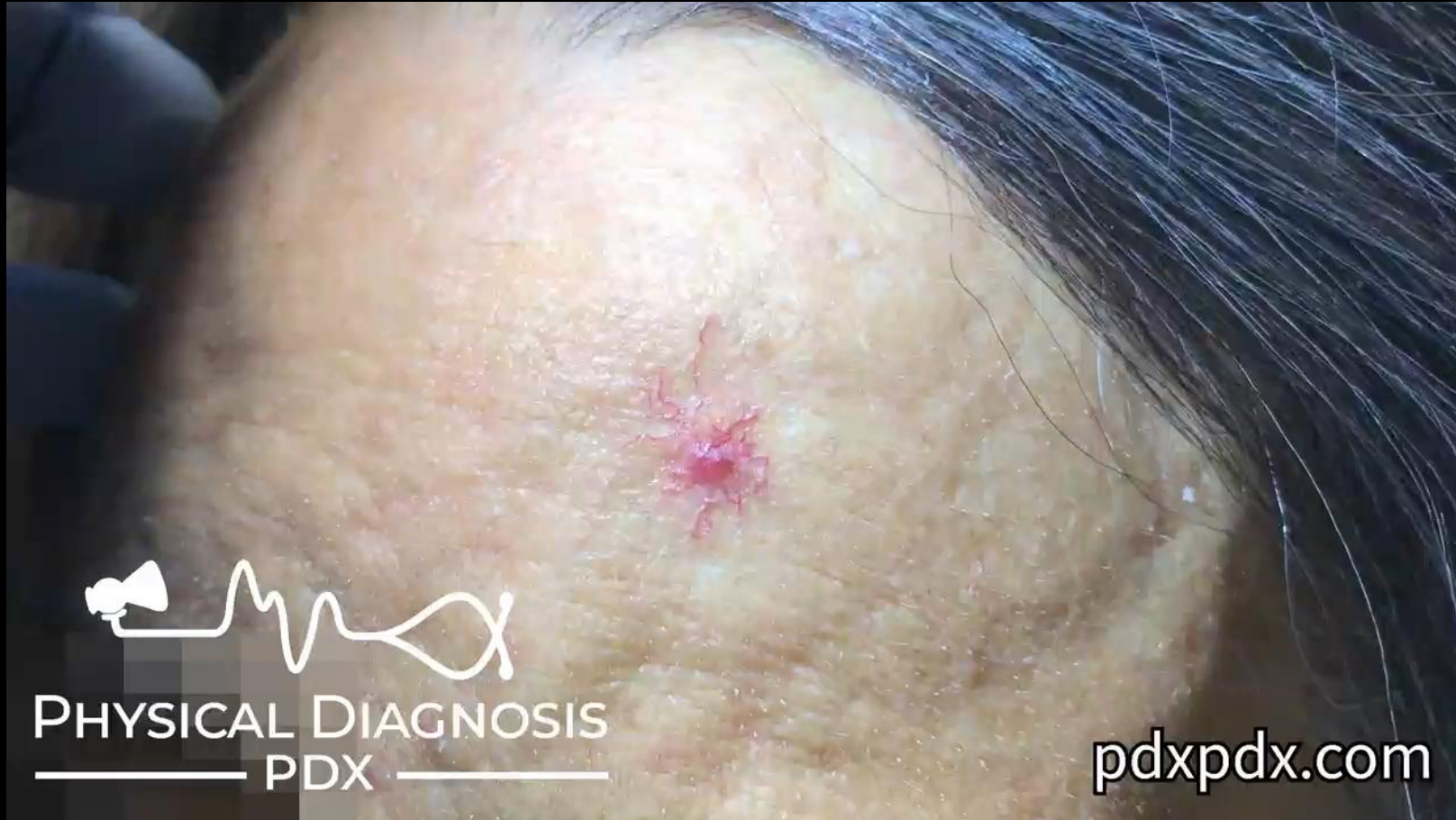Patient Consent

- All patients consented to having images taken and shared for educational purposes

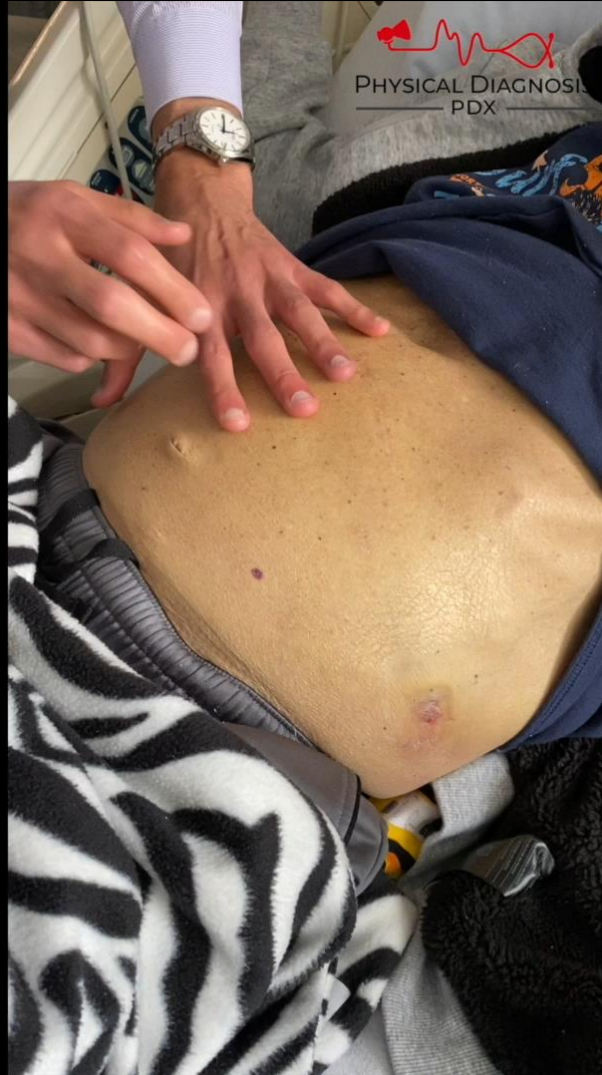Case #1: 46 y/o woman with fatigue



Case #1: 46 y/o woman with fatigue



Case #1: 46 y/o woman with fatigue



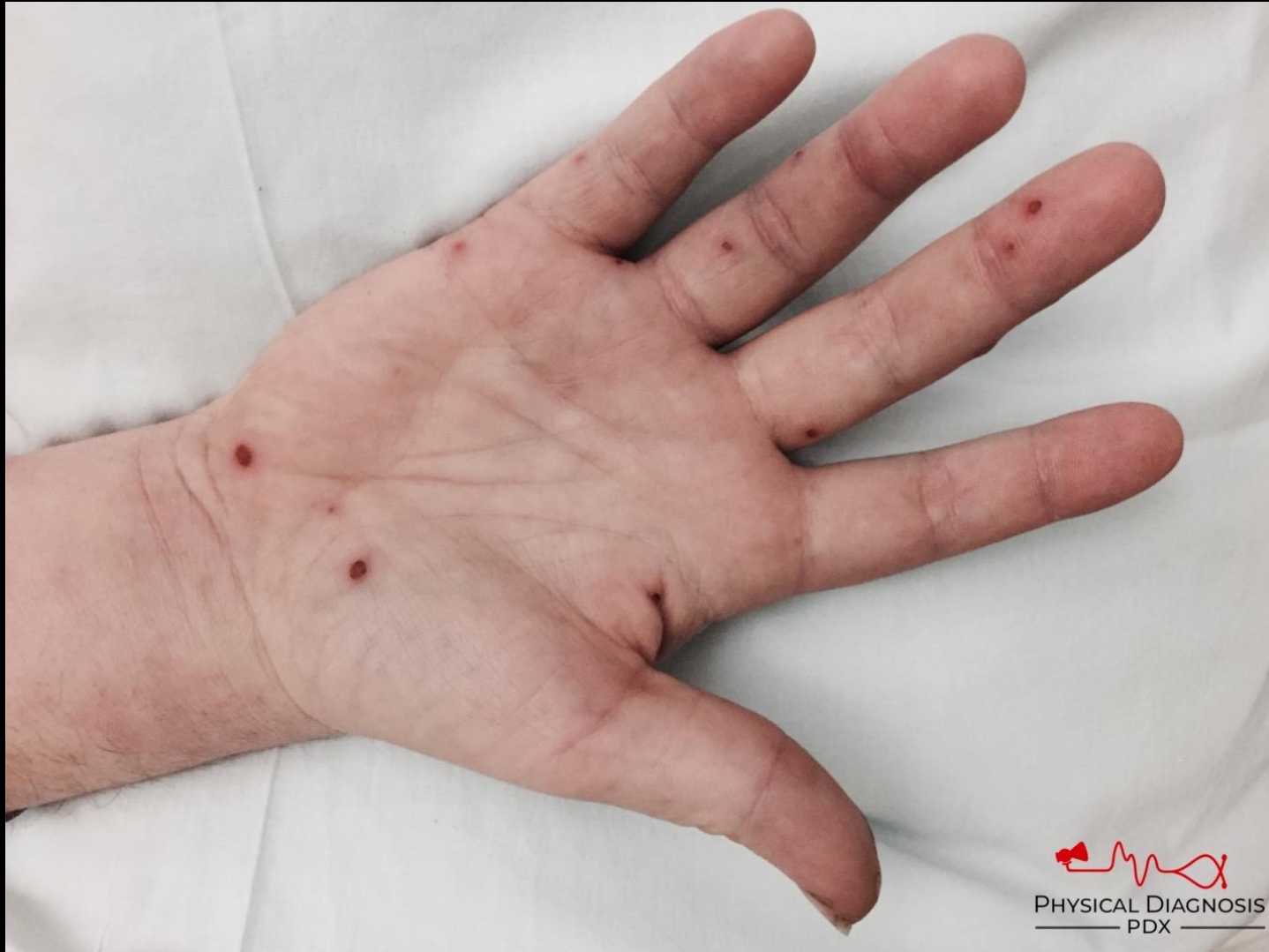Case #1: 46 y/o woman with fatigue

- Clinical findings:
 - Jaundice
 - Spider angiomas
 - Palmar erythema
 - Ascites
- **Underlying diagnosis: ?**

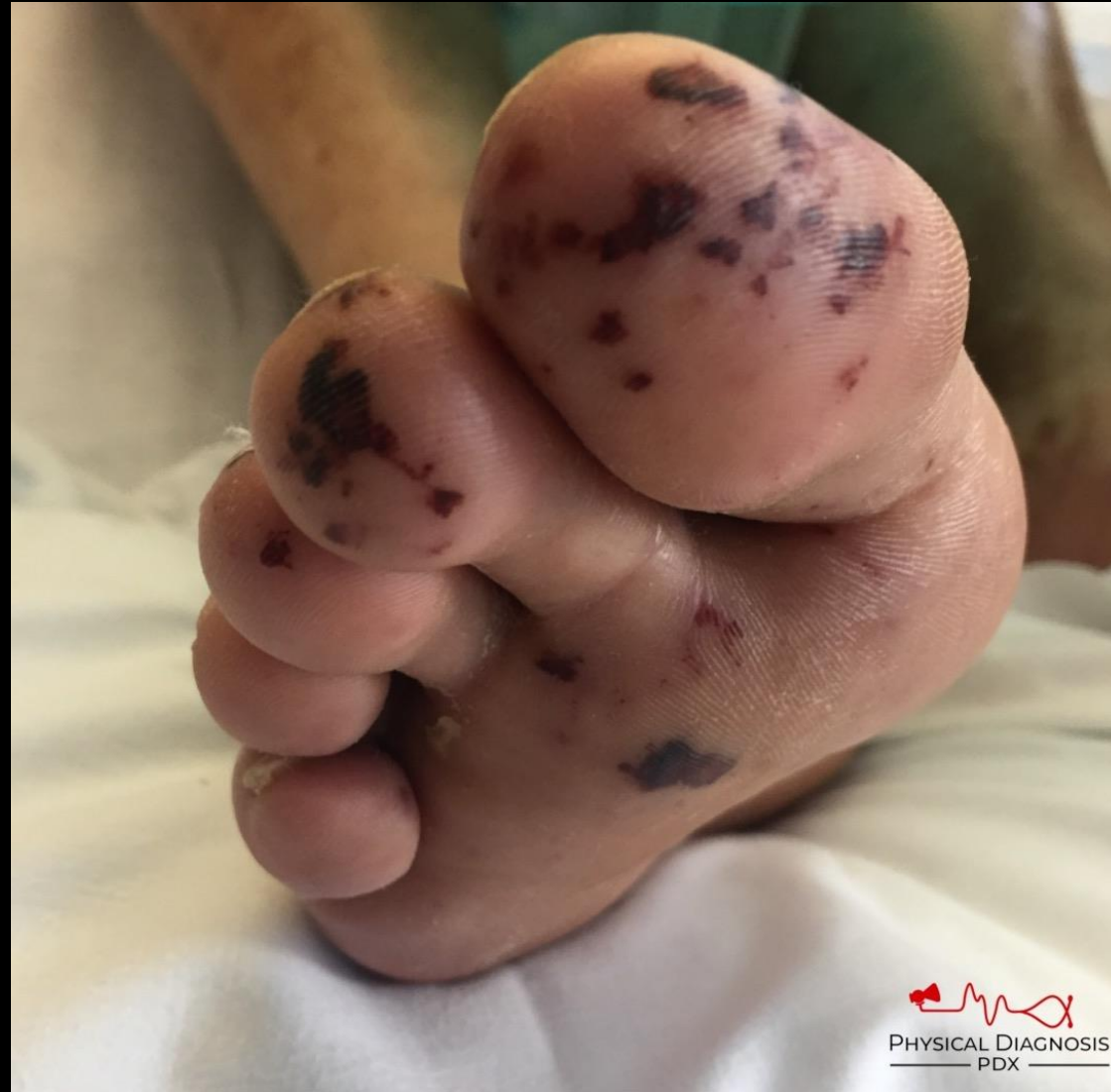Case #1: 46 y/o woman with fatigue

- Clinical findings:
 - Jaundice
 - Spider angiomas
 - Palmar erythema
 - Ascites
- Underlying diagnosis: **Cirrhosis**

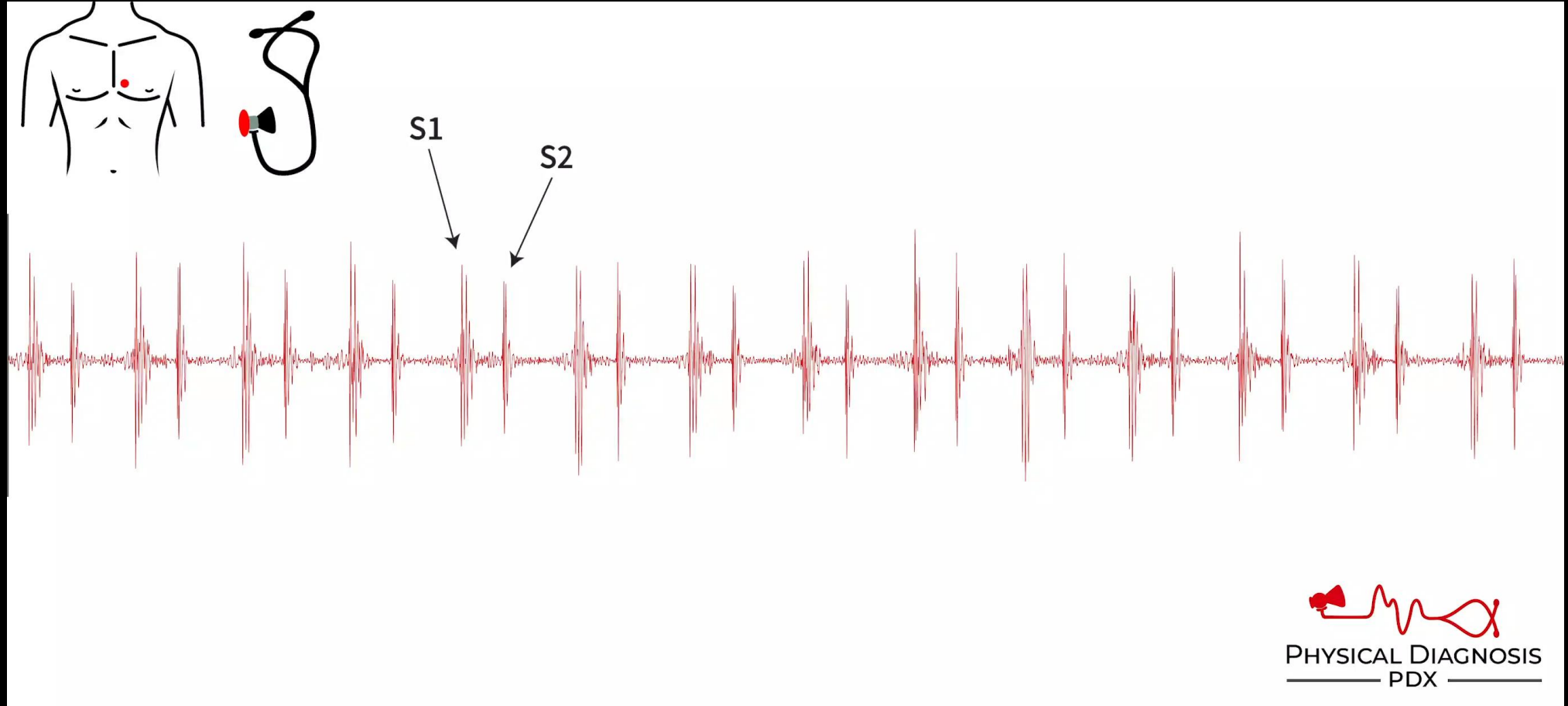
Case #2: 28 y/o man with fever and chills



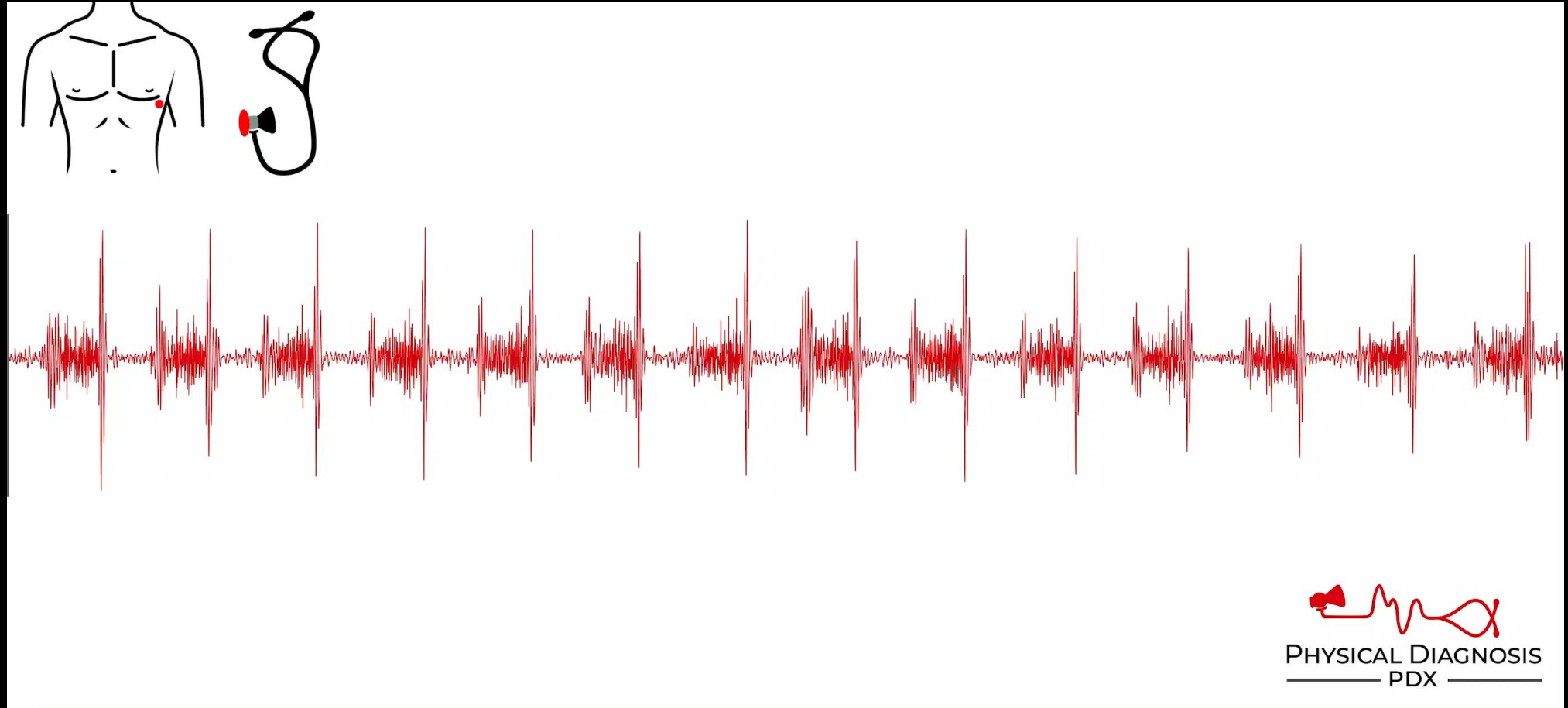
Case #2: 28 y/o man with fever and chills



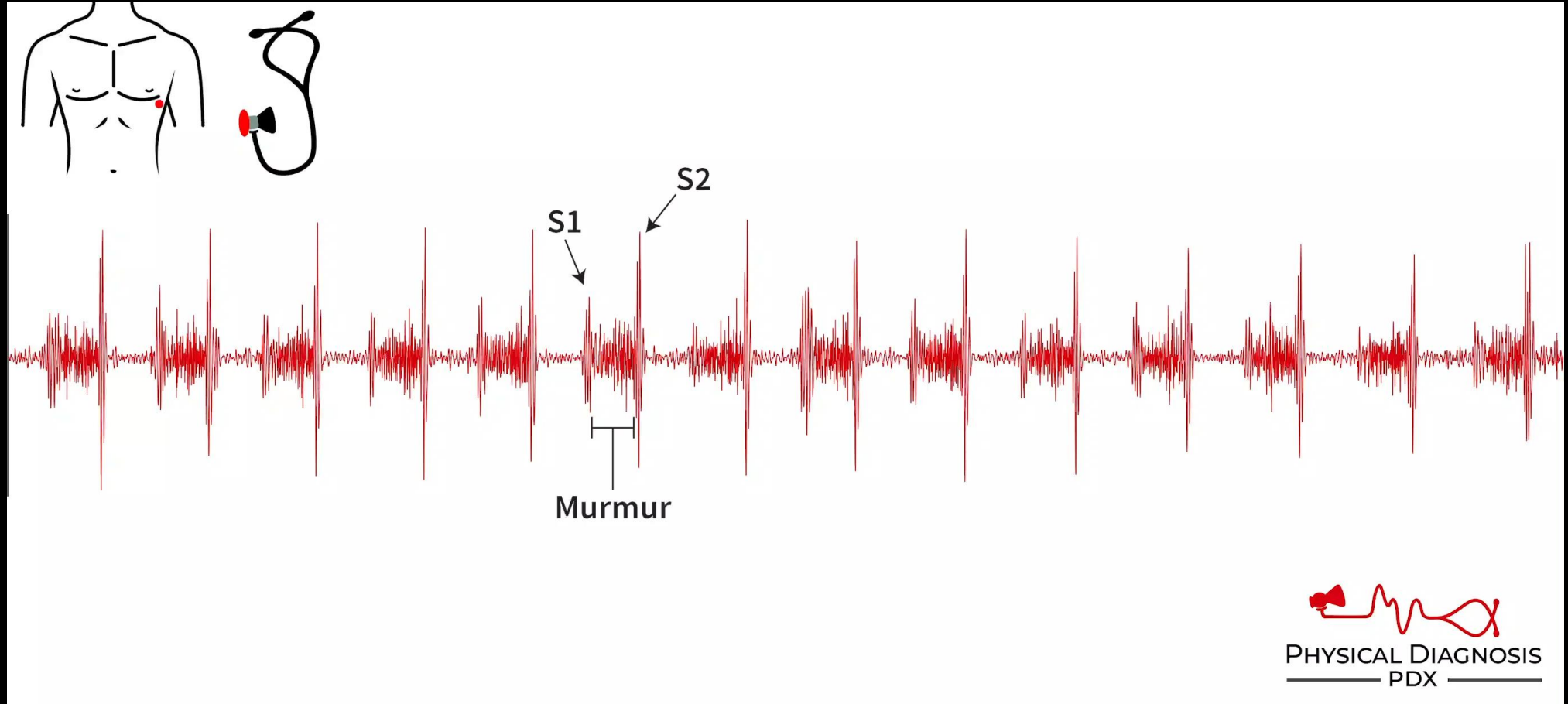
Case #2: 28 y/o man with fever and chills



Case #2: 28 y/o man with fever and chills



Case #2: 28 y/o man with fever and chills



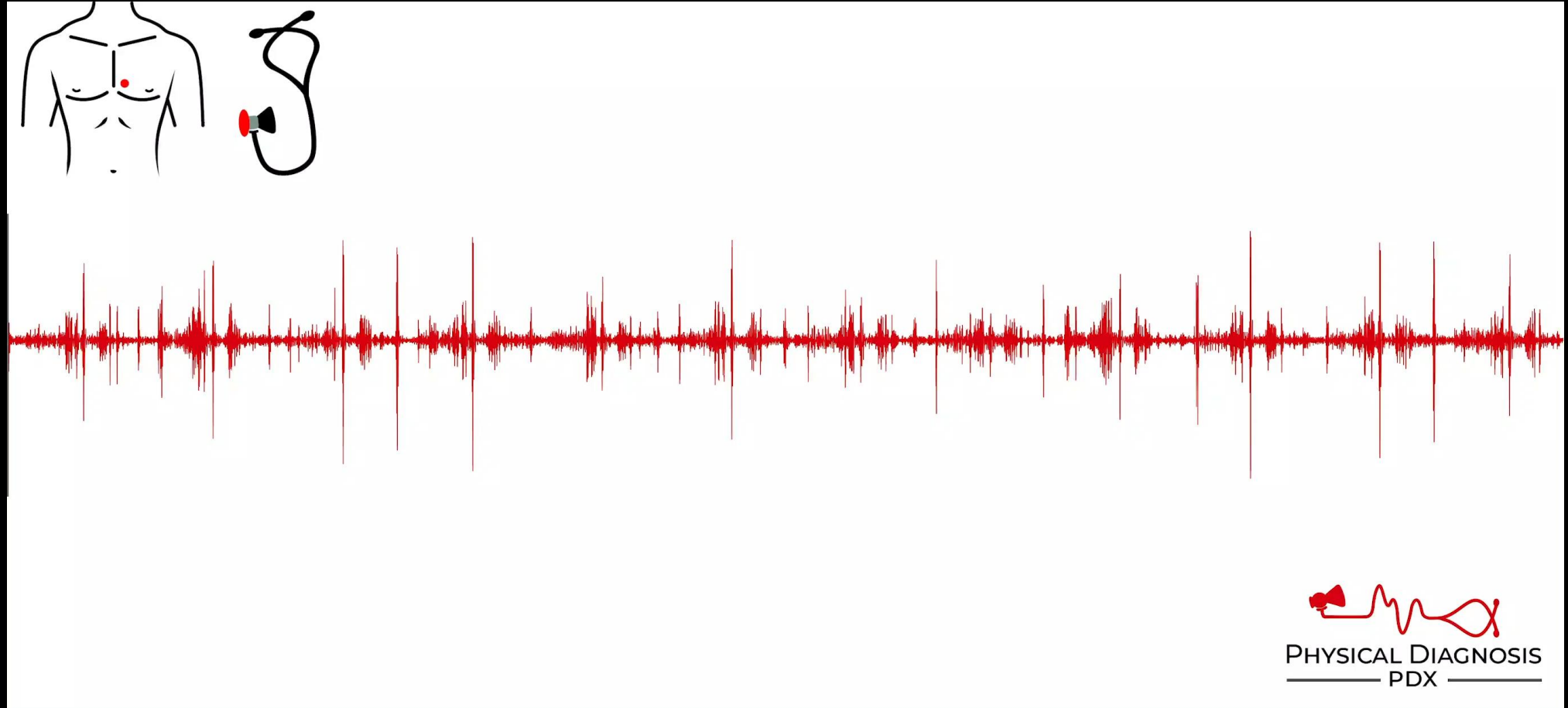
Case #2: 28 y/o man with fever and chills

- Clinical findings:
 - Osler's nodes
 - Janeway lesions
 - Heart murmur
- **Underlying diagnosis: ?**

Case #2: 28 y/o man with fever and chills

- Clinical findings:
 - Osler's nodes
 - Janeway lesions
 - Heart murmur
- **Underlying diagnosis: Endocarditis**

Case #2: 28 y/o man with fever and chills



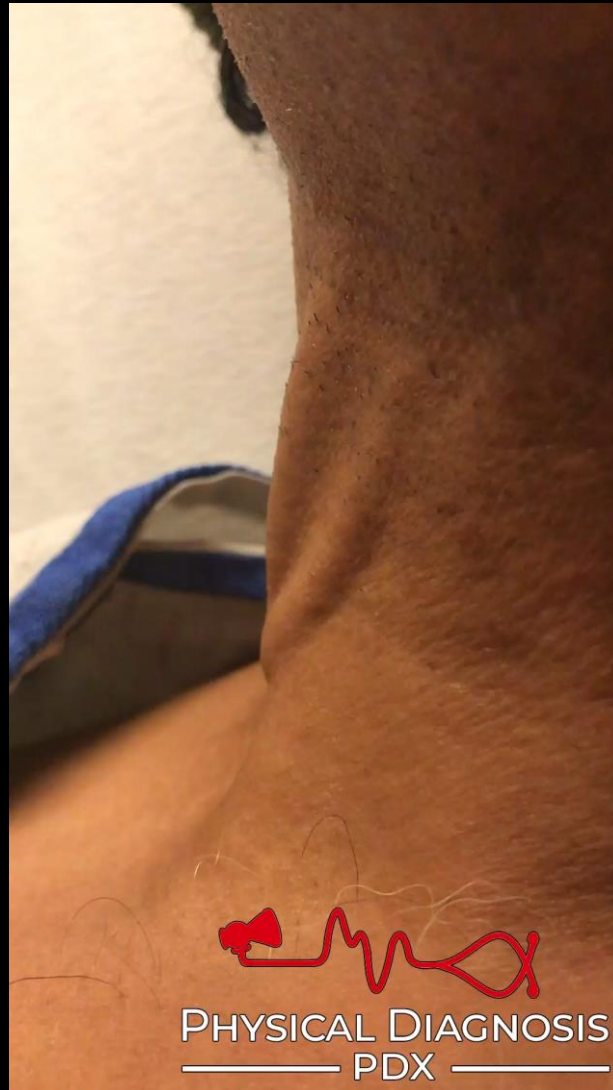Case #2: 28 y/o man with fever and chills

- 3-component pericardial friction rub

Case #2: 28 y/o man with fever and chills

- Patient becomes hypotensive and presyncopal
- Rub has gone away
- Heart sounds more distant
- And his neck looked like this. . .

Case #2: 28 y/o man with fever and chills



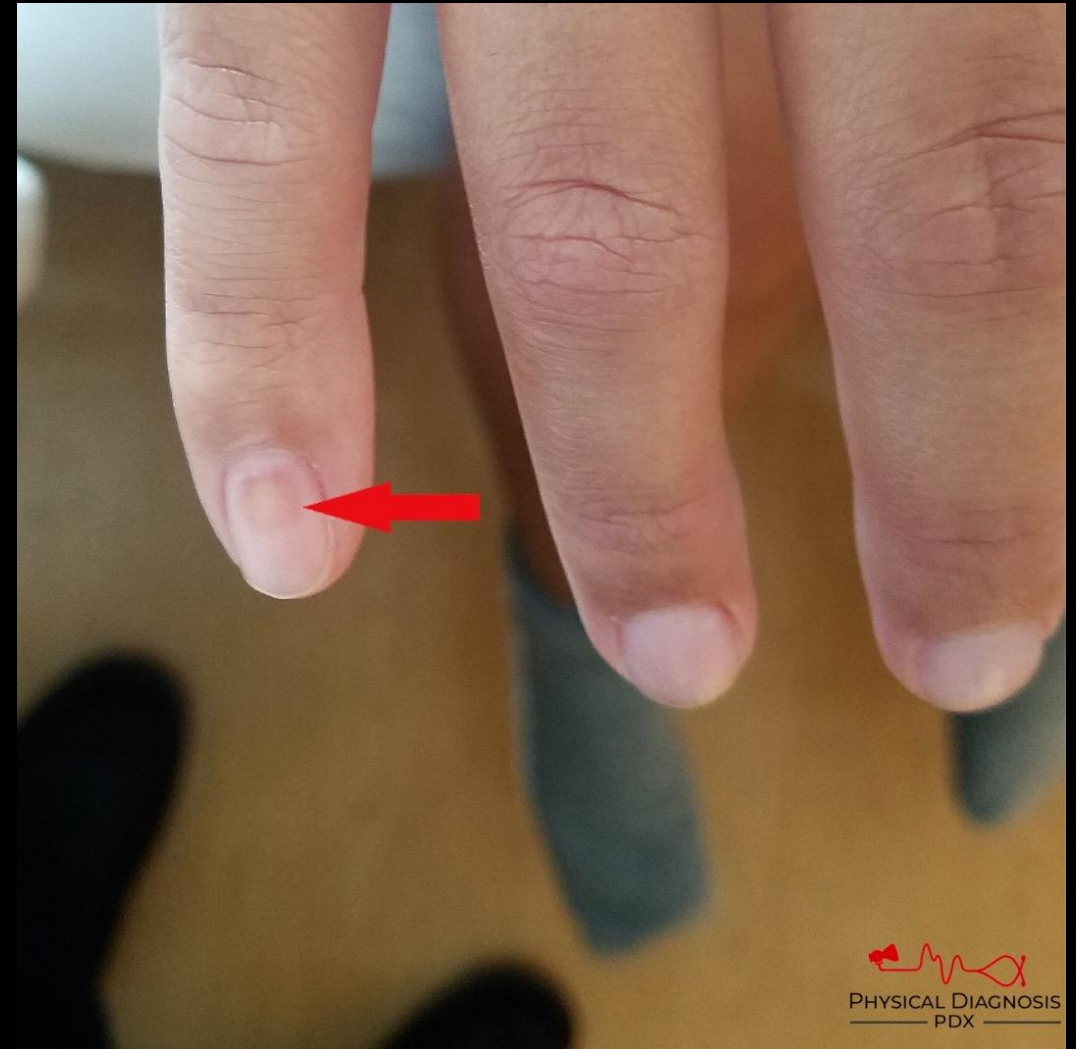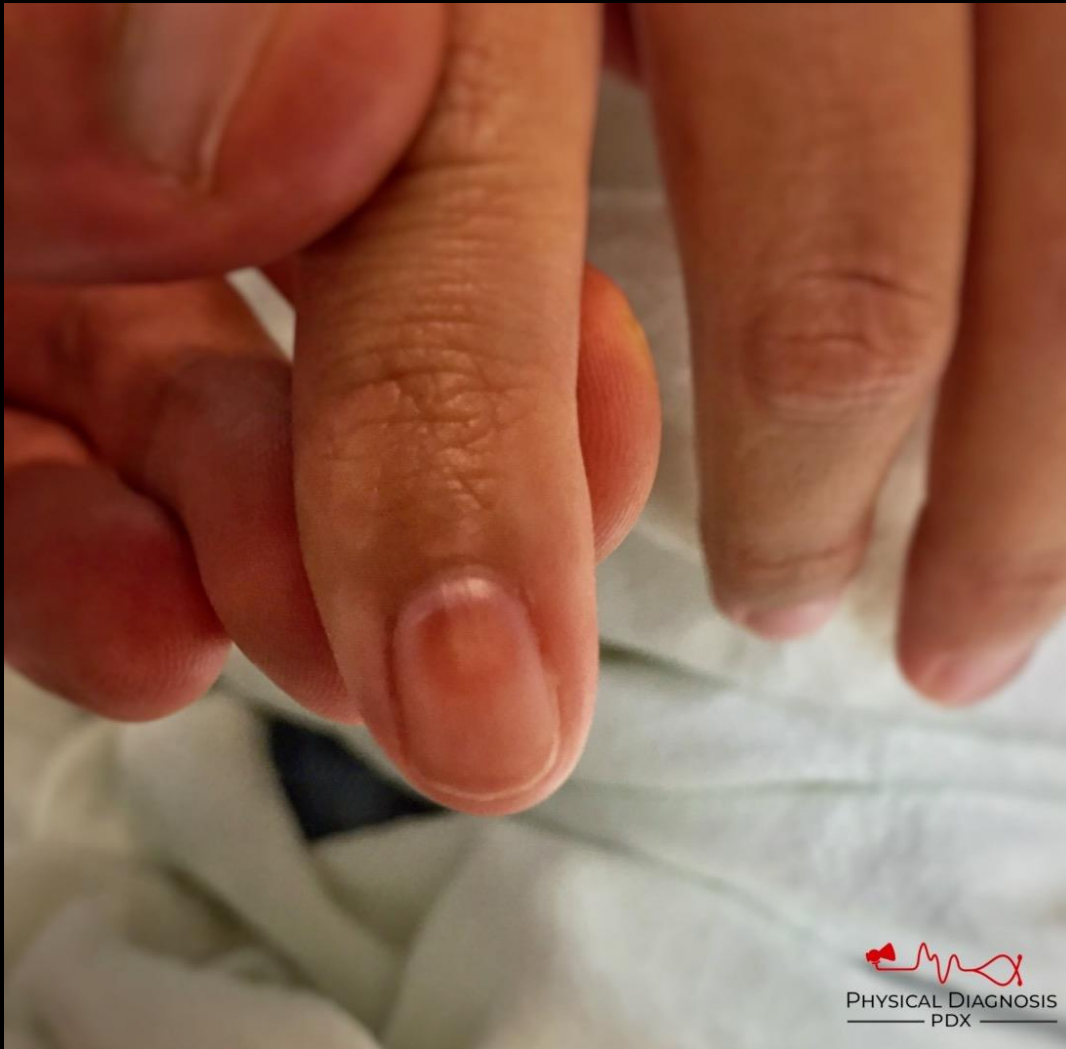Case #2: 28 y/o man with fever and chills

- Clinical findings:
 - Distant heart sounds
 - Hypotension
 - Elevated JVP
- **Underlying diagnosis: ?**

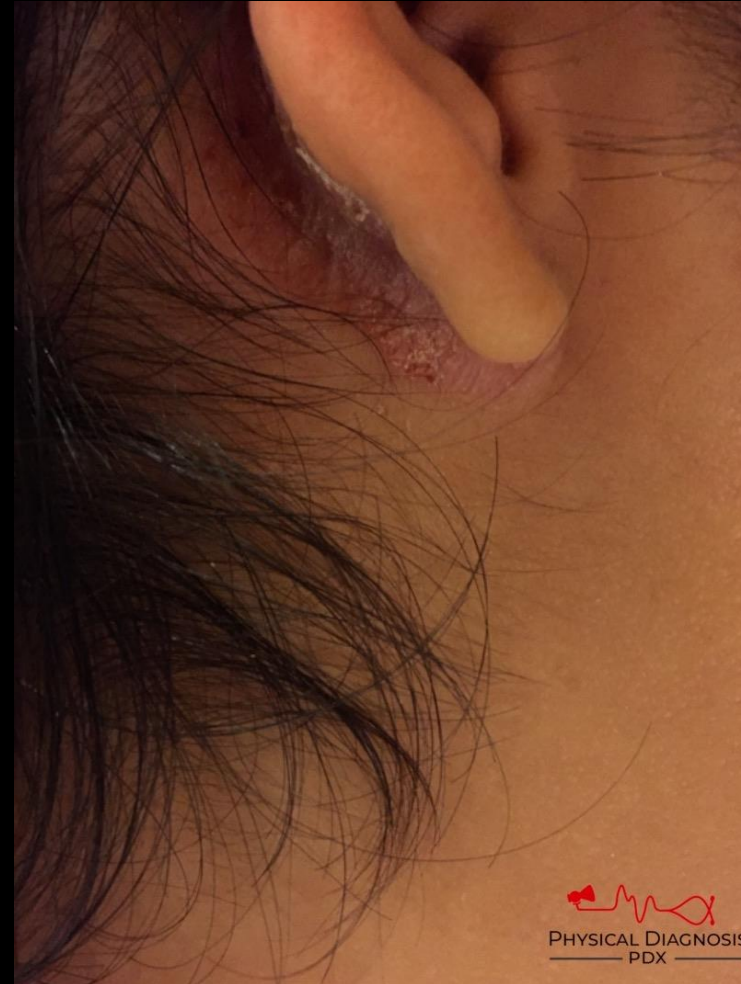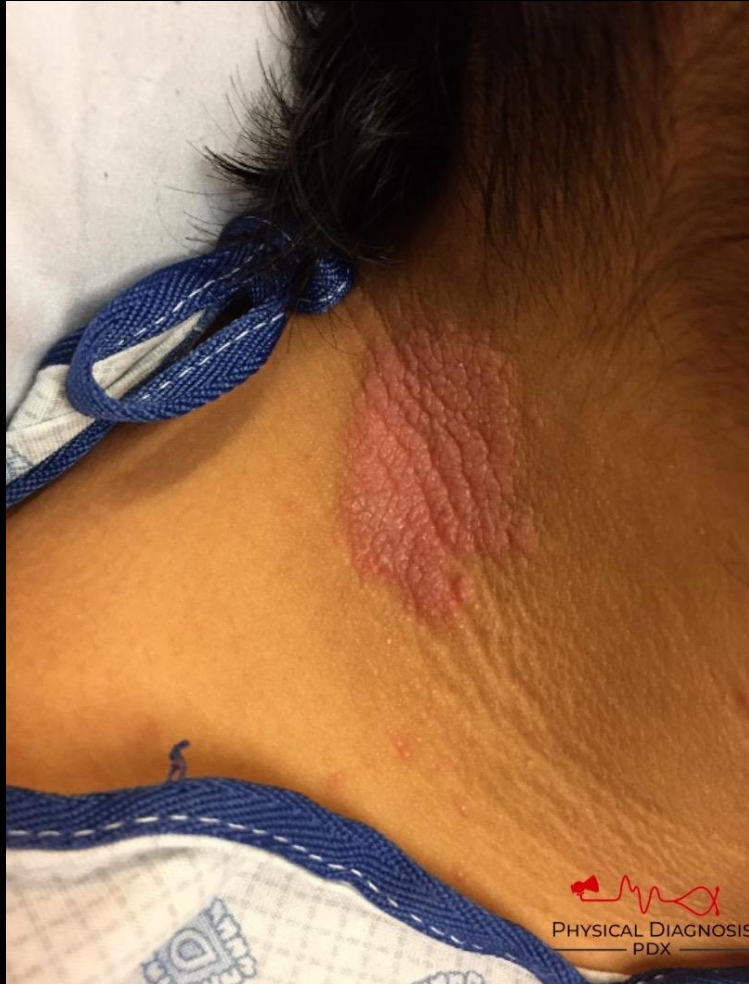Case #2: 28 y/o man with fever and chills

- Clinical findings:
 - Distant heart sounds
 - Hypotension
 - Elevated JVP
- **Underlying diagnosis: Tamponade**

Case #3: 24 y/o woman with joint pain



Case #3: 24 y/o woman with joint pain



Case #3: 24 y/o woman with joint pain

- Clinical findings:
 - Oil drop sign
 - Psoriatic plaques
- **Underlying diagnosis: ?**

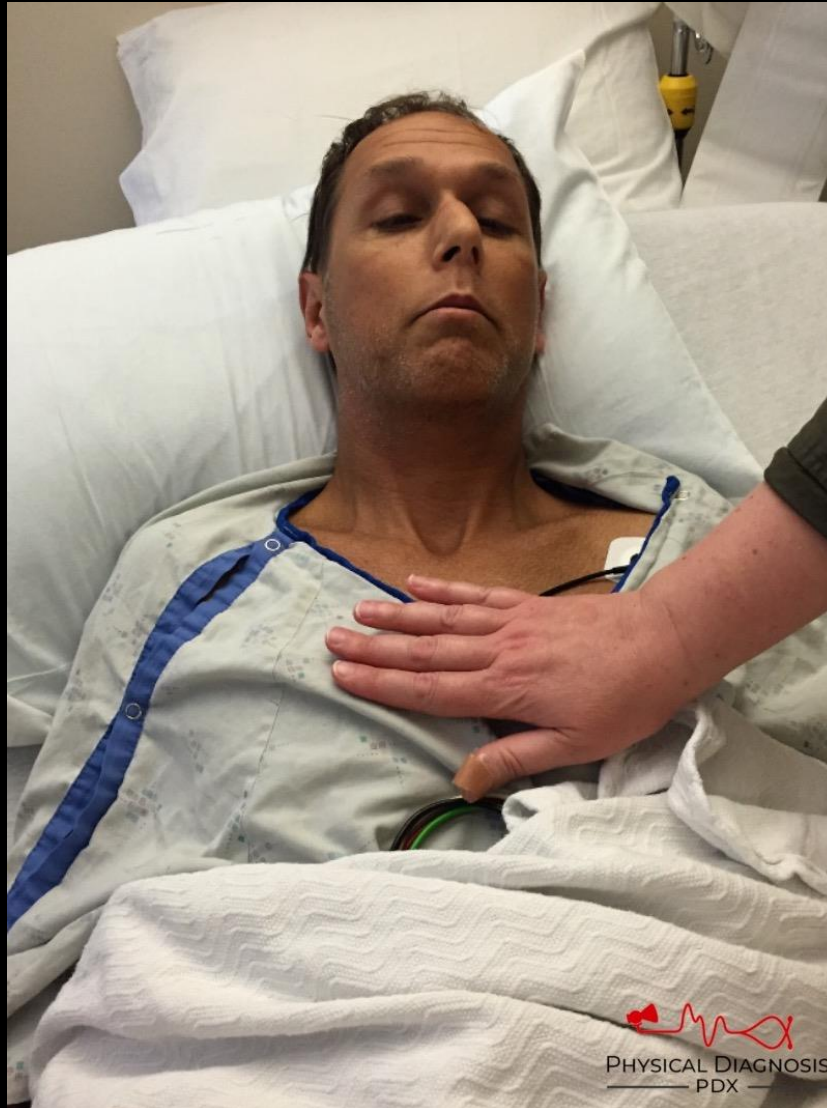Case #3: 24 y/o woman with joint pain

- Clinical findings:
 - Oil drop sign
 - Psoriatic plaques
- **Underlying diagnosis: Psoriatic arthritis**

Case #4: 34 y/o woman with light-headedness



Case #4: 34 y/o woman with light-headedness



Case #4: 34 y/o woman with light-headedness



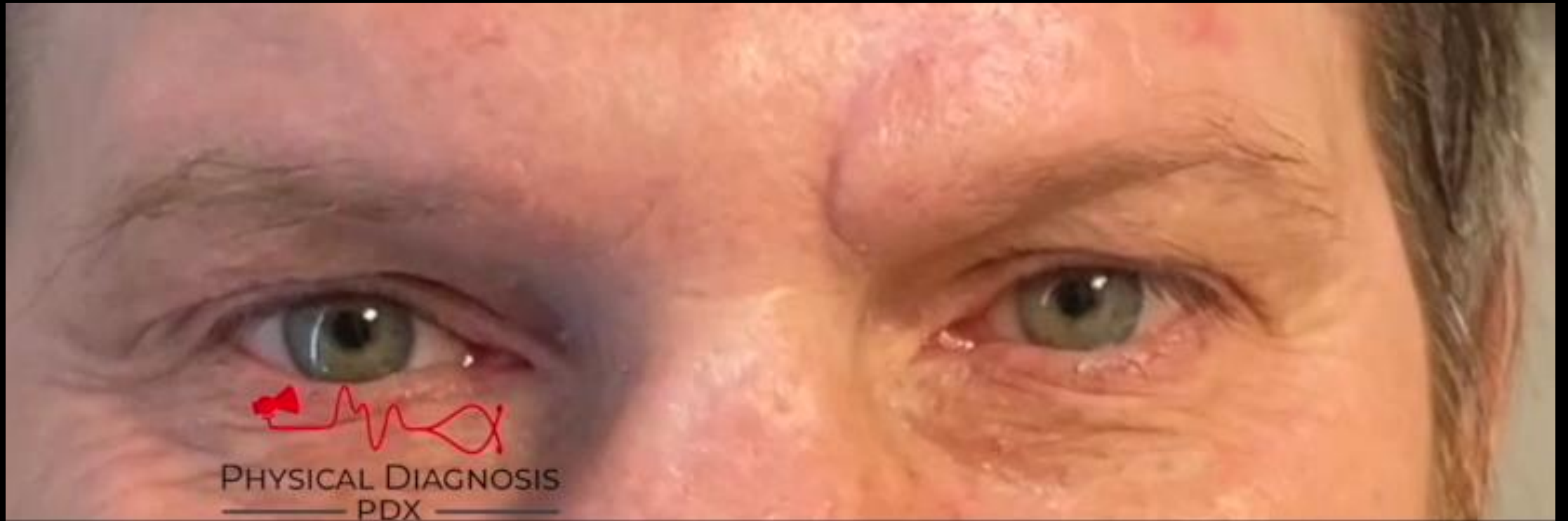Case #4: 34 y/o woman with light-headedness

- Clinical findings:
 - Hyperpigmentation
- **Underlying diagnosis: ?**

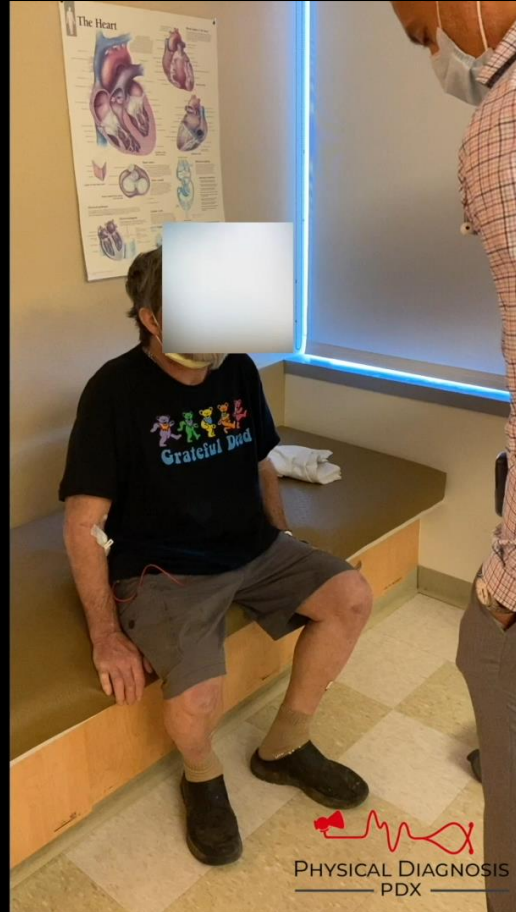Case #4: 34 y/o woman with light-headedness

- Clinical findings:
 - Hyperpigmentation
- **Underlying diagnosis: Adrenal insufficiency**

Case #5: 60 y/o man with confusion



Case #5: 60 y/o man with confusion



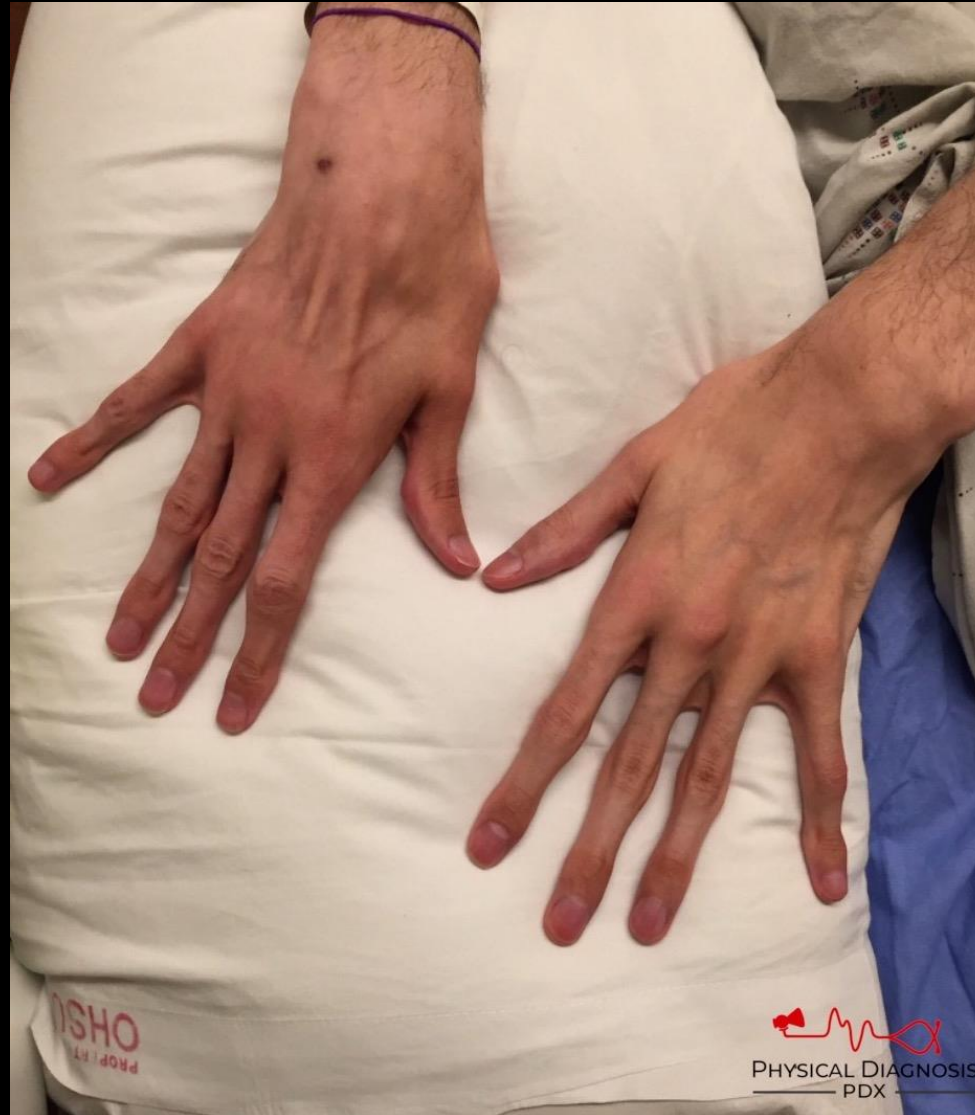Case #5: 60 y/o man with confusion

- Clinical findings:
 - Nystagmus
 - Confabulation
- **Underlying diagnosis: ?**

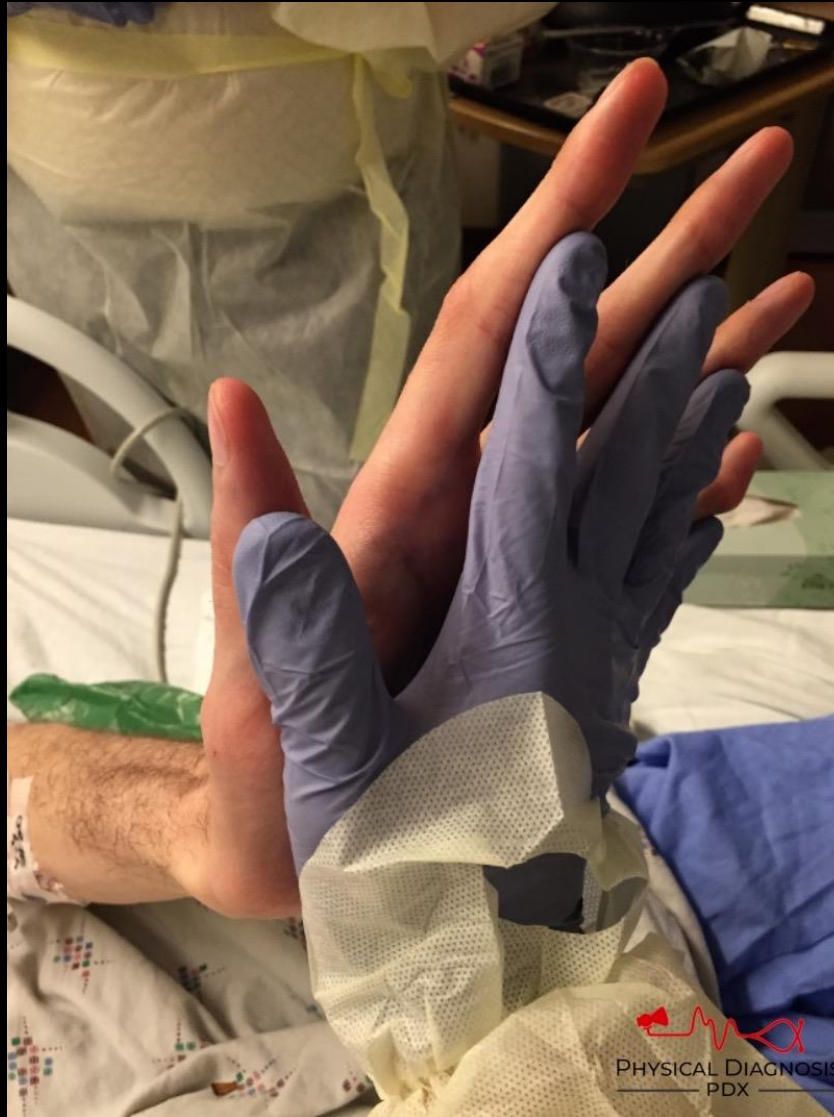Case #5: 60 y/o man with confusion

- Clinical findings:
 - Nystagmus
 - Confabulation
- **Underlying diagnosis: Wernicke-Korsakoff syndrome**

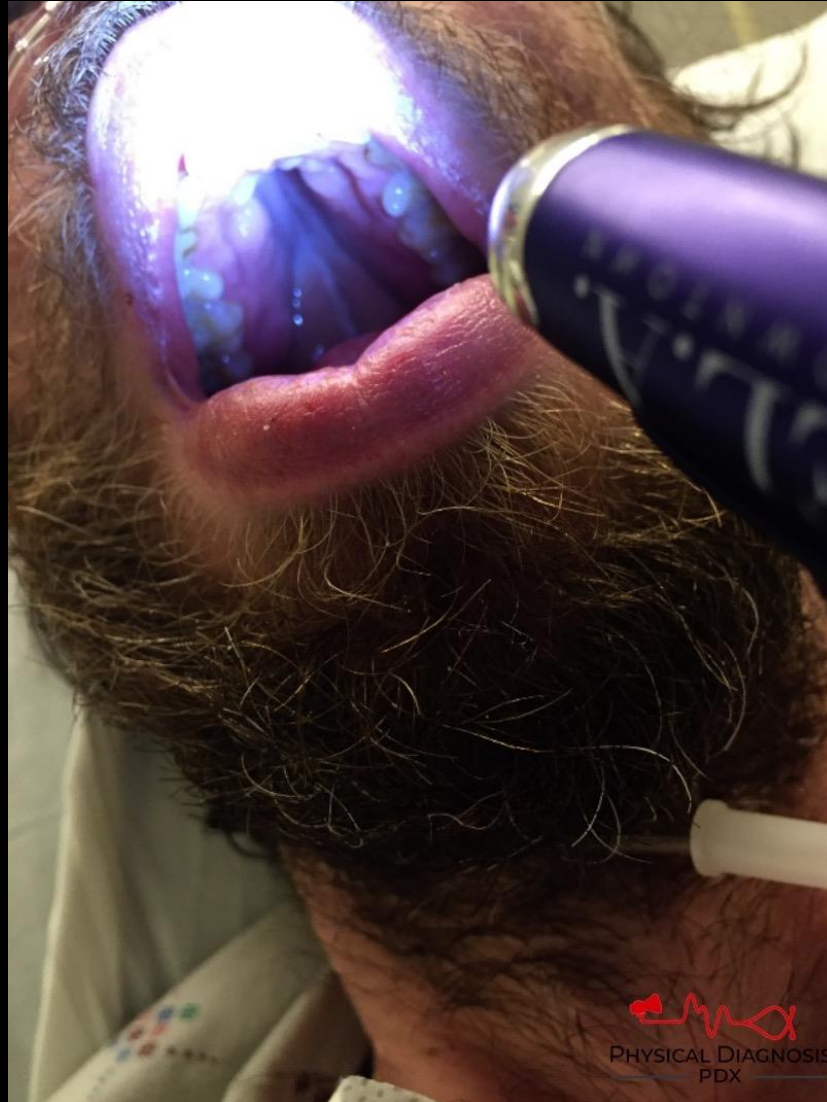Case #6: 25 y/o man with blurry vision



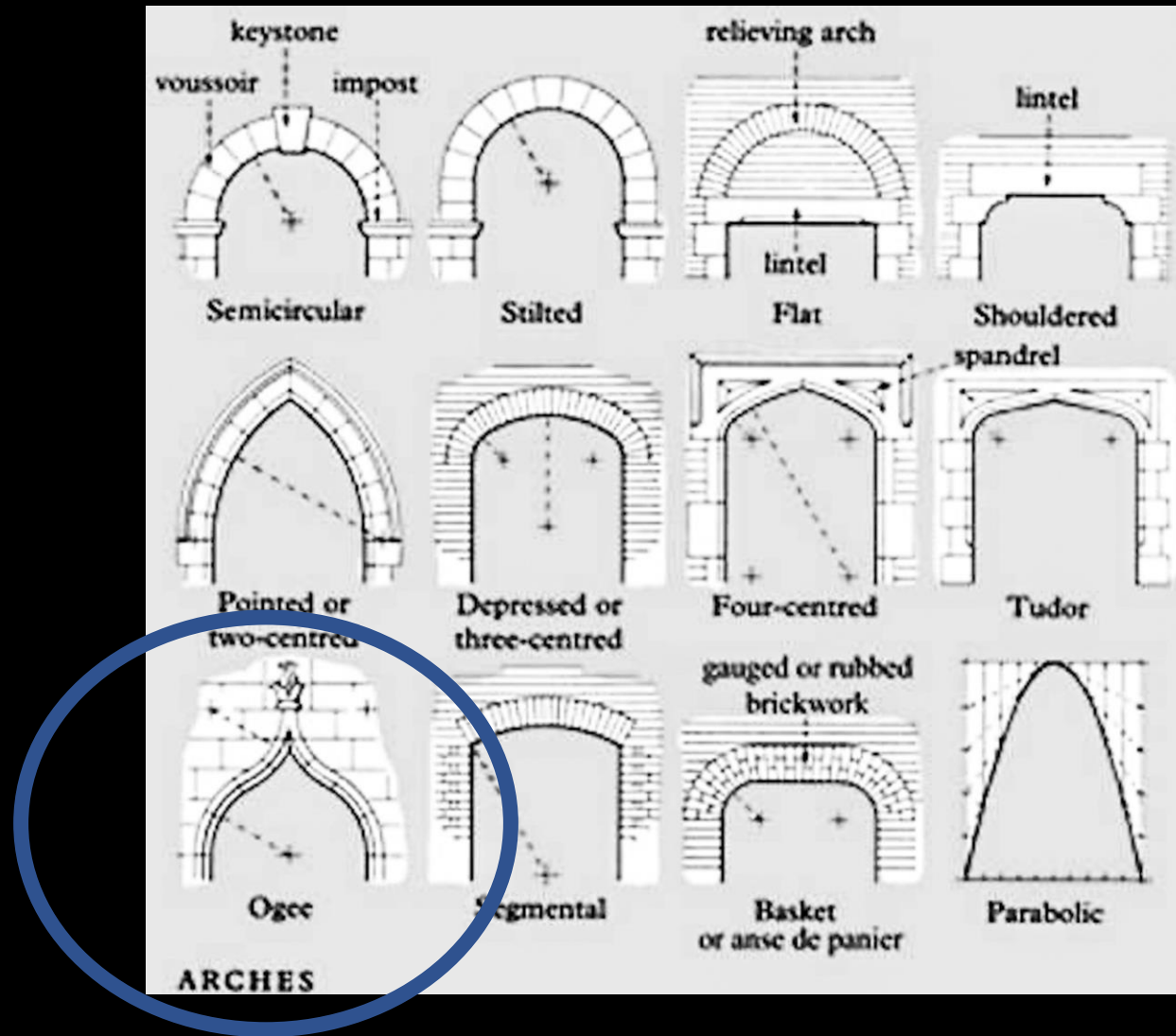
Case #6: 25 y/o man with blurry vision



Case #6: 25 y/o man with blurry vision



Case #6: 25 y/o man with blurry vision



Case #6: 25 y/o man with blurry vision



Case #6: 25 y/o man with blurry vision



Case #6: 25 y/o man with blurry vision



Case #6: 25 y/o man with blurry vision



Case #6: 25 y/o man with blurry vision



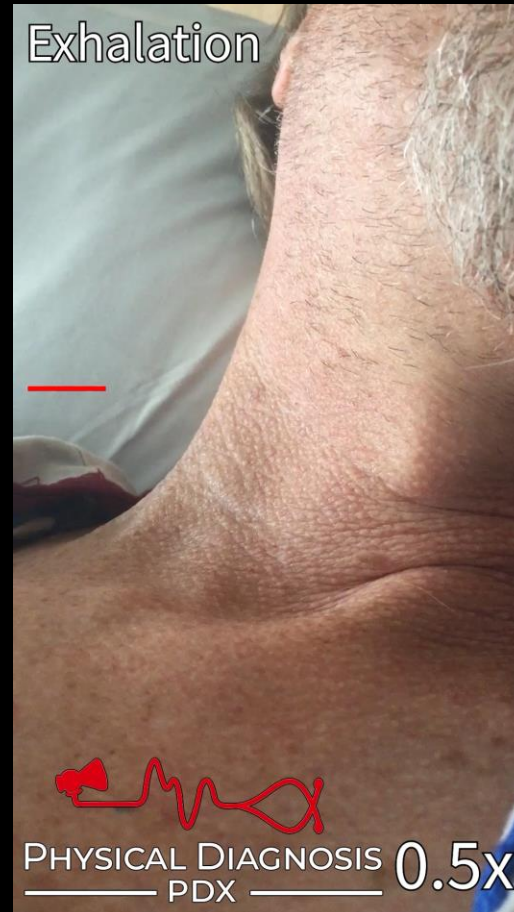Case #6: 25 y/o man with blurry vision

- Clinical findings:
 - Arachnodactyly
 - High-arched palate (ogival palate)
- **Underlying diagnosis: ?**

Case #6: 25 y/o man with blurry vision

- Clinical findings:
 - Arachnodactyly
 - High-arched palate (ogival palate)
- **Underlying diagnosis: Marfan's syndrome**

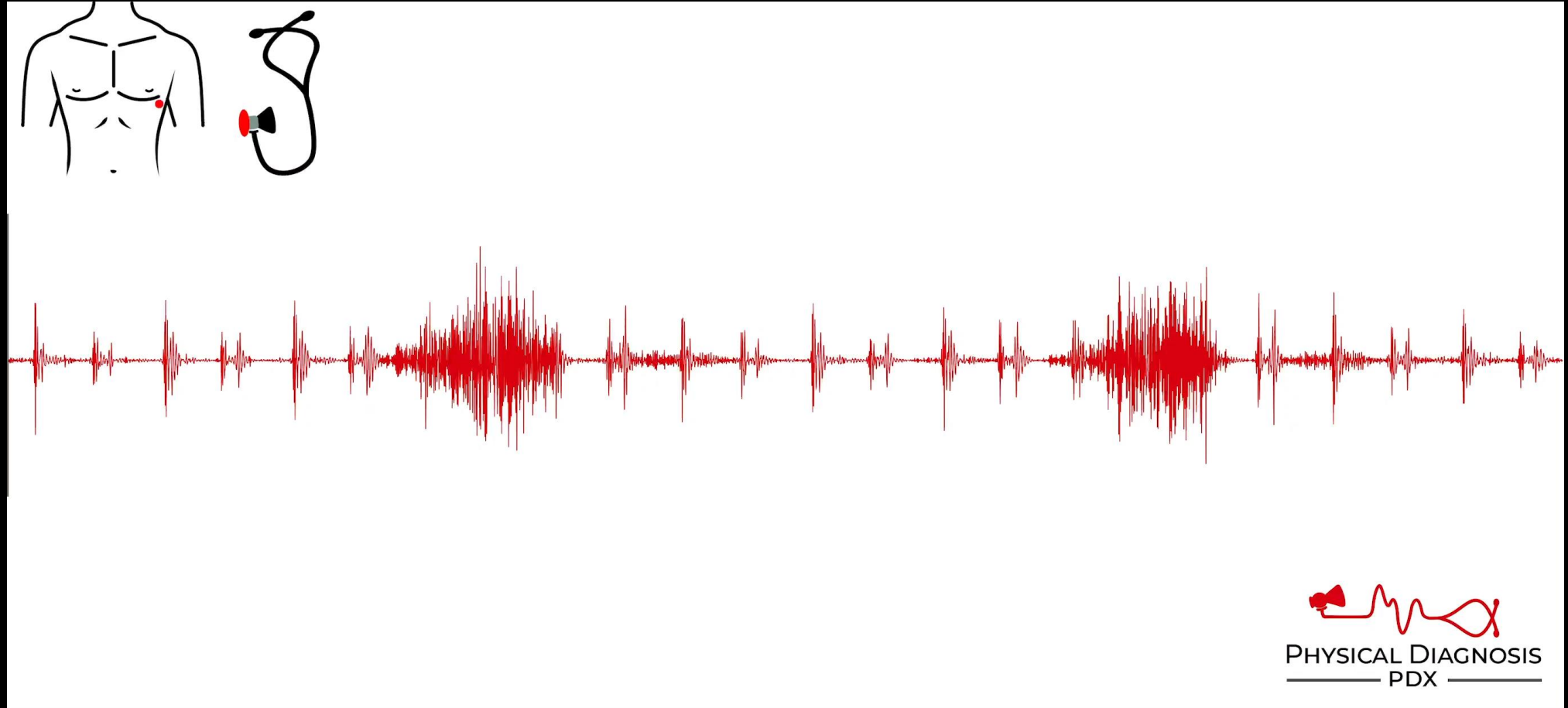
Case #7: 65 y/o man with dyspnea



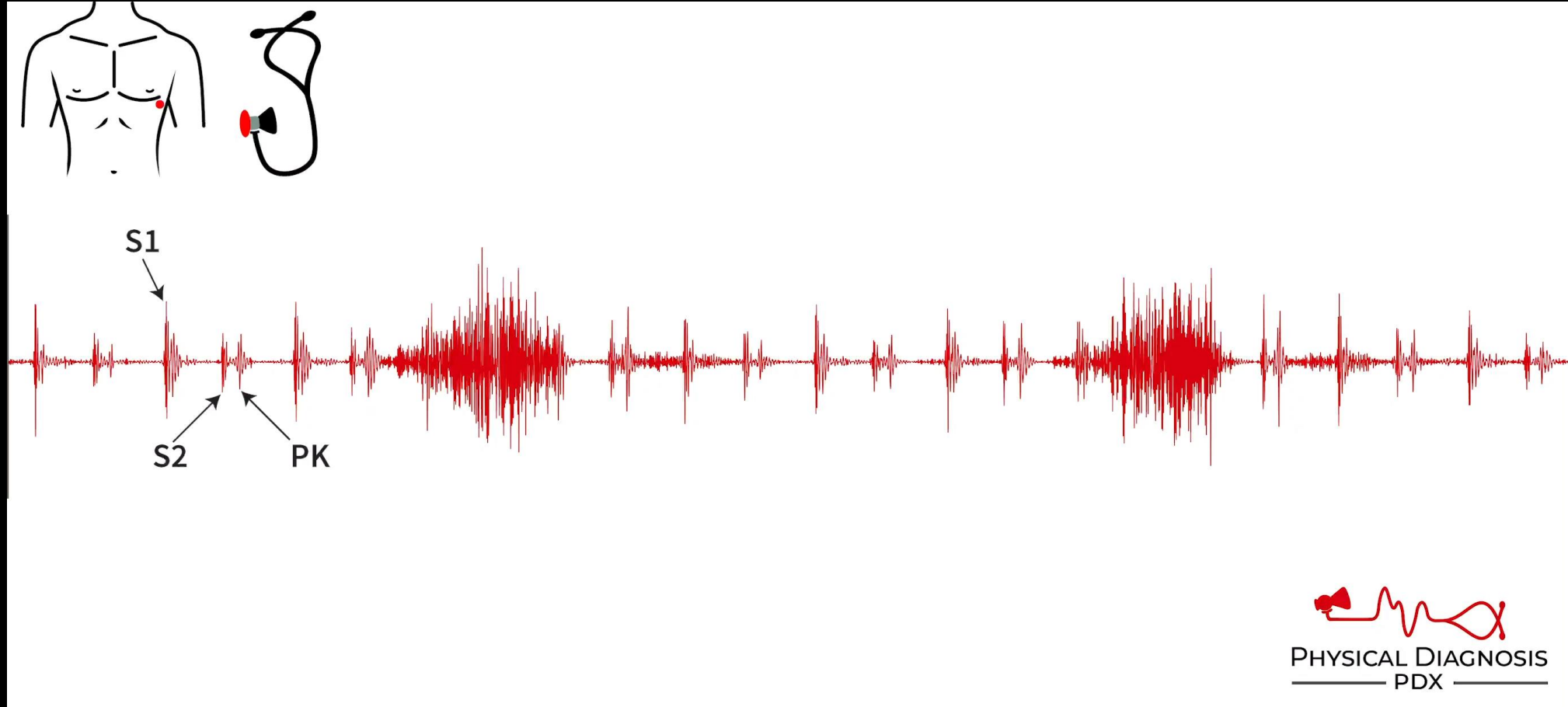
Case #7: 65 y/o man with dyspnea



Case #7: 65 y/o man with dyspnea



Case #7: 65 y/o man with dyspnea



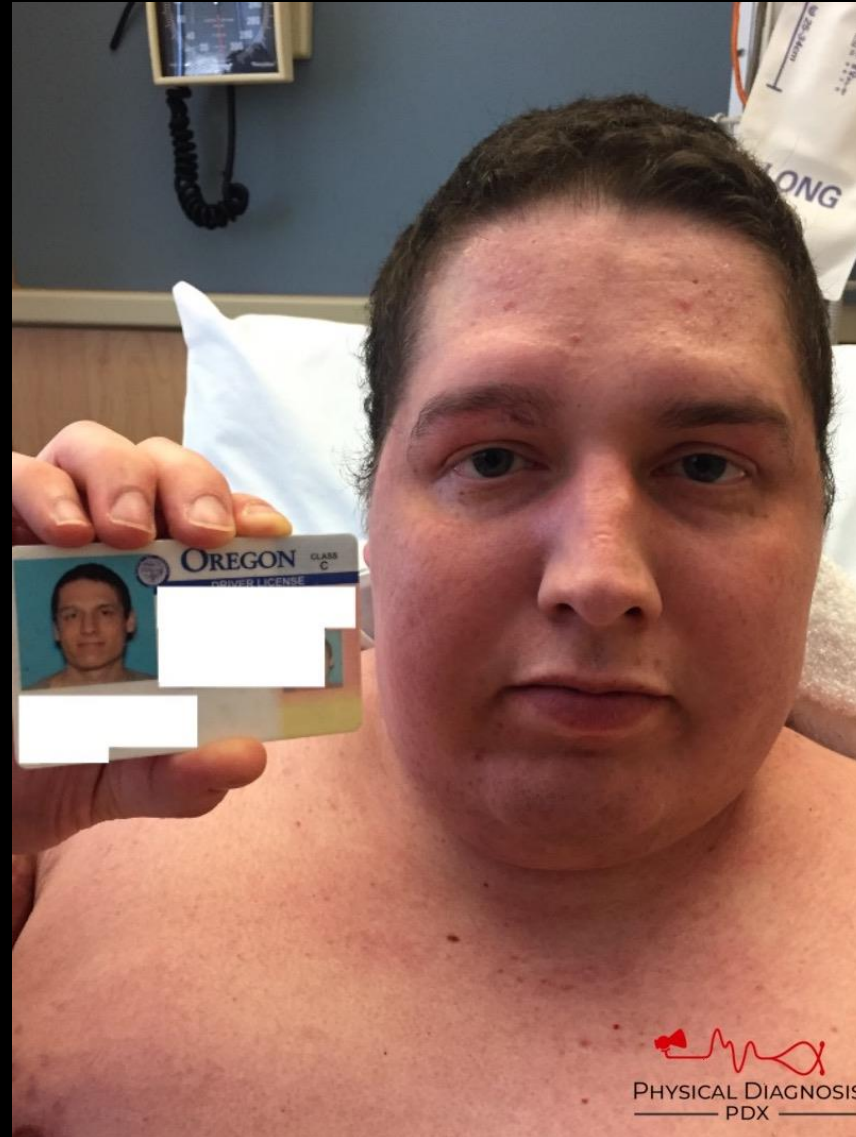Case #7: 65 y/o man with dyspnea

- Clinical findings:
 - Kussmaul's sign
 - Radiation tattoo marker
 - Pericardial knock
- **Underlying diagnosis: ?**

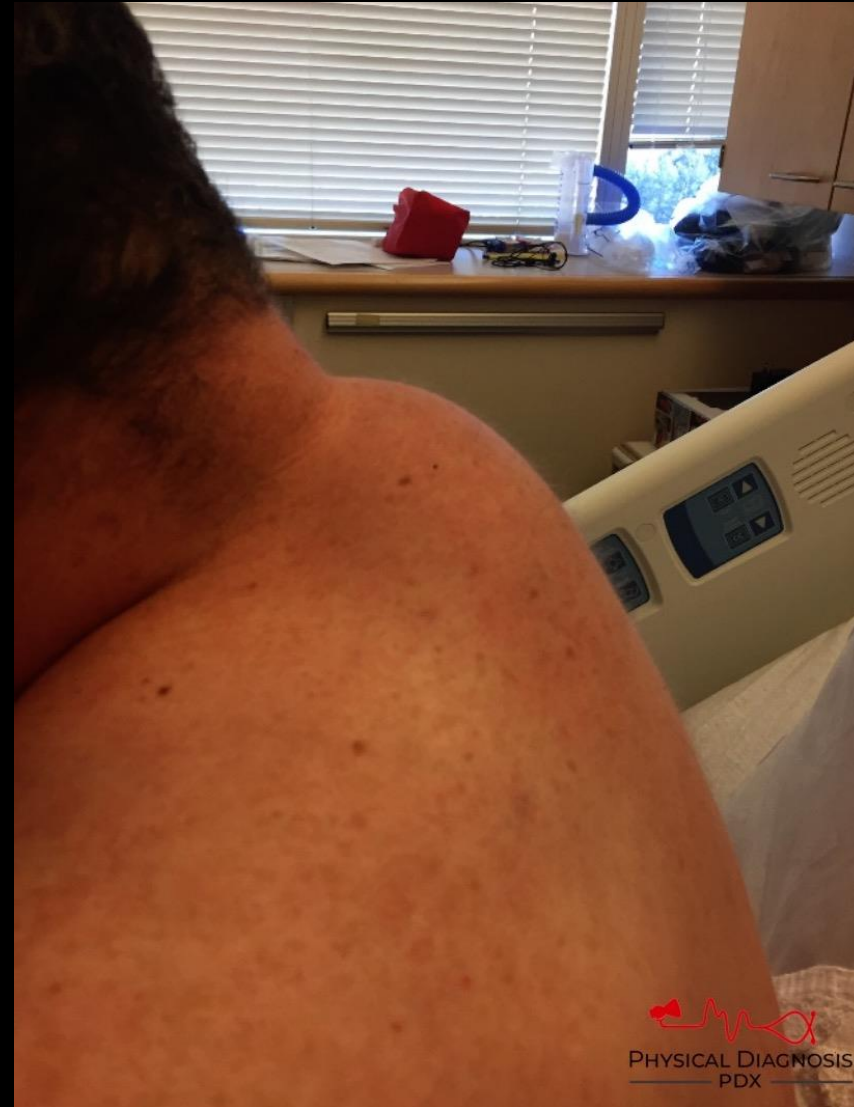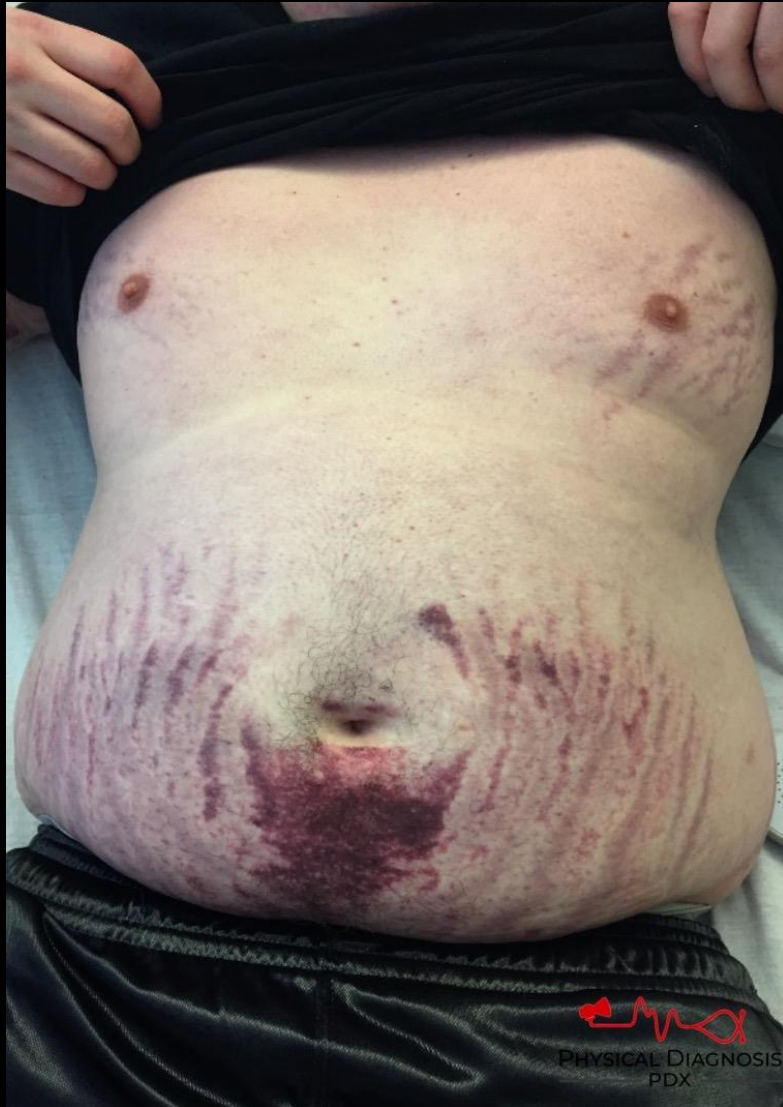Case #7: 65 y/o man with dyspnea

- Clinical findings:
 - Kussmaul's sign
 - Radiation tattoo marker
 - Pericardial knock
- **Underlying diagnosis: Constrictive pericarditis**

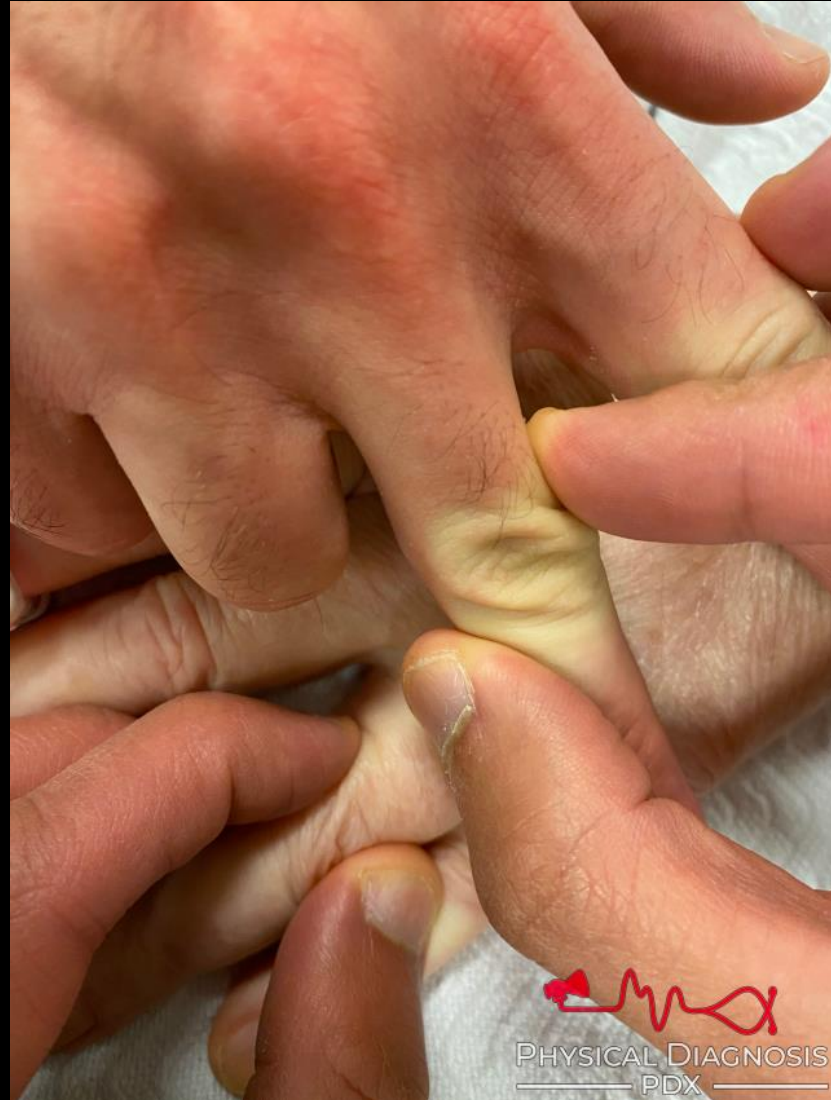Case #8: 28 y/o man with rapid weight gain



Case #8: 28 y/o man with rapid weight gain



Case #8: 28 y/o man with rapid weight gain



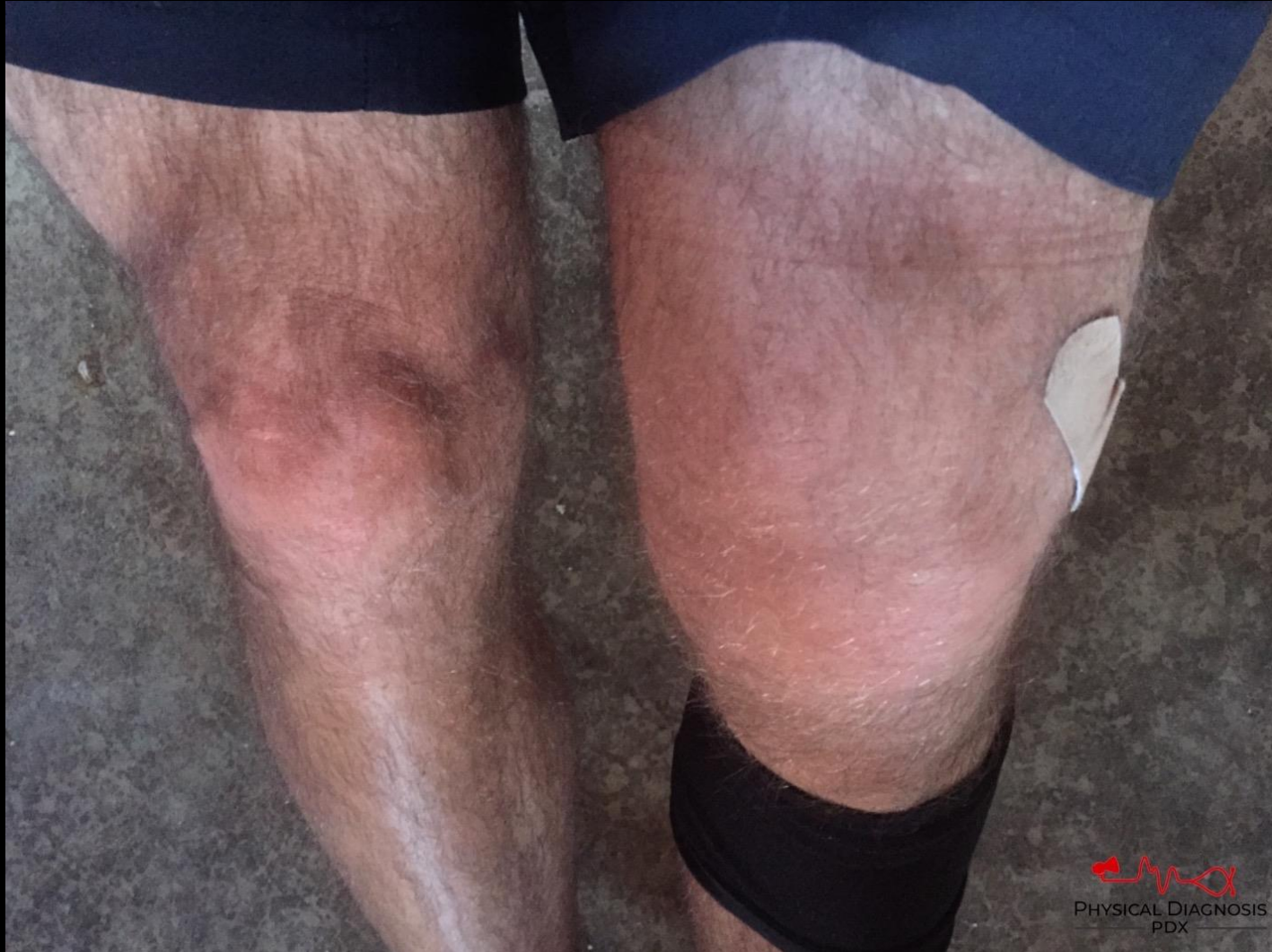Case #8: 28 y/o man with rapid weight gain

- Clinical findings:
 - Moon facies
 - Acne
 - Abdominal striae
 - Buffalo hump
 - Thin skin
- **Underlying diagnosis: ?**

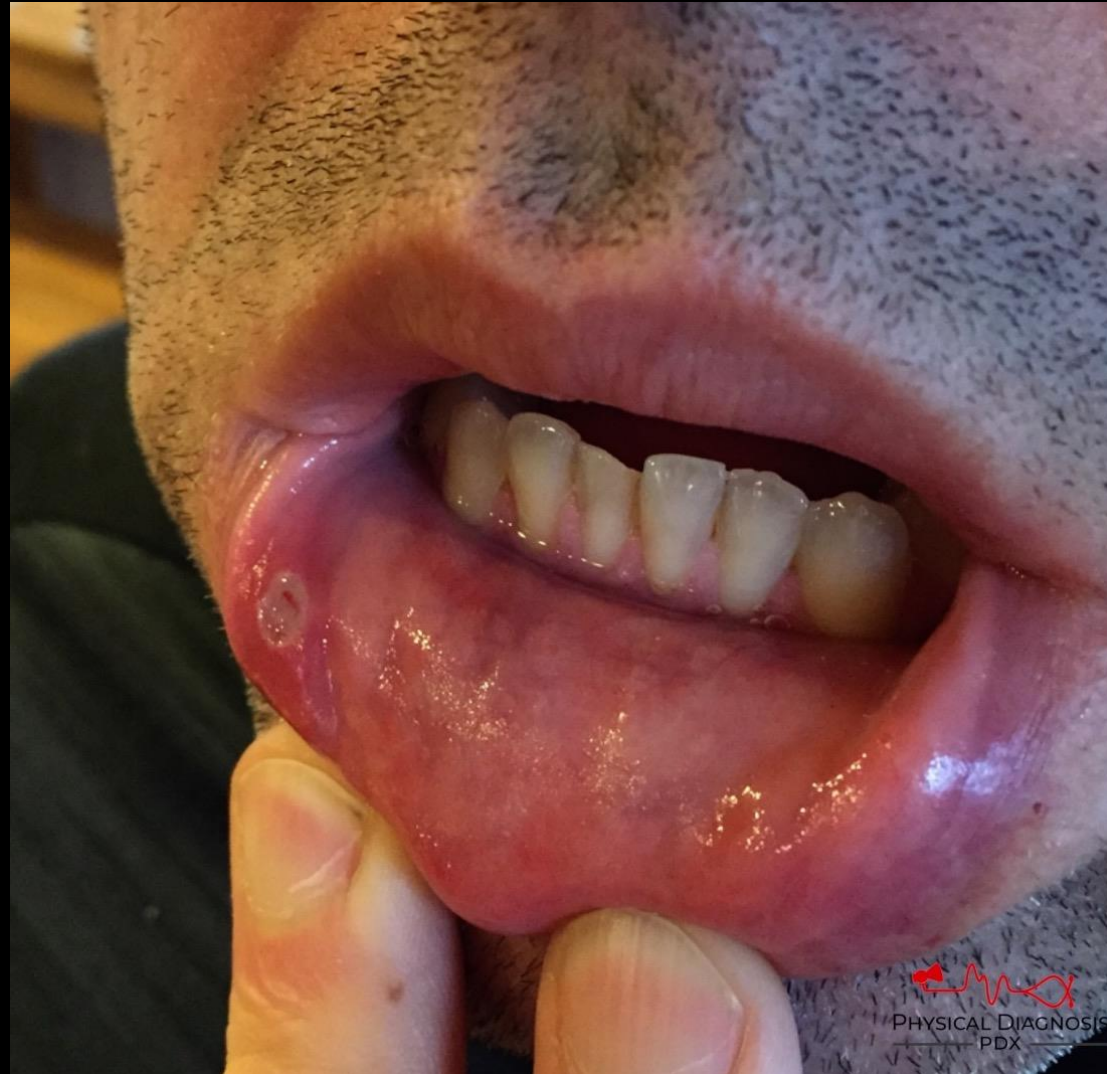Case #8: 28 y/o man with rapid weight gain

- Clinical findings:
 - Moon facies
 - Acne
 - Abdominal striae
 - Buffalo hump
 - Thin skin
- Underlying diagnosis: **Cushing's syndrome**

Case #9: 37 y/o man with a painful knee



Case #9: 37 y/o man with a painful knee



Case #9: 37 y/o man with a painful knee

- Clinical findings:
 - Arthritis
 - Oral ulcers
- **Underlying diagnosis: ?**

Case #9: 37 y/o man with a painful knee

- Clinical findings:
 - Arthritis
 - Oral ulcers
- Underlying diagnosis: **Reactive arthritis**

Case #9: 37 y/o man with a painful knee



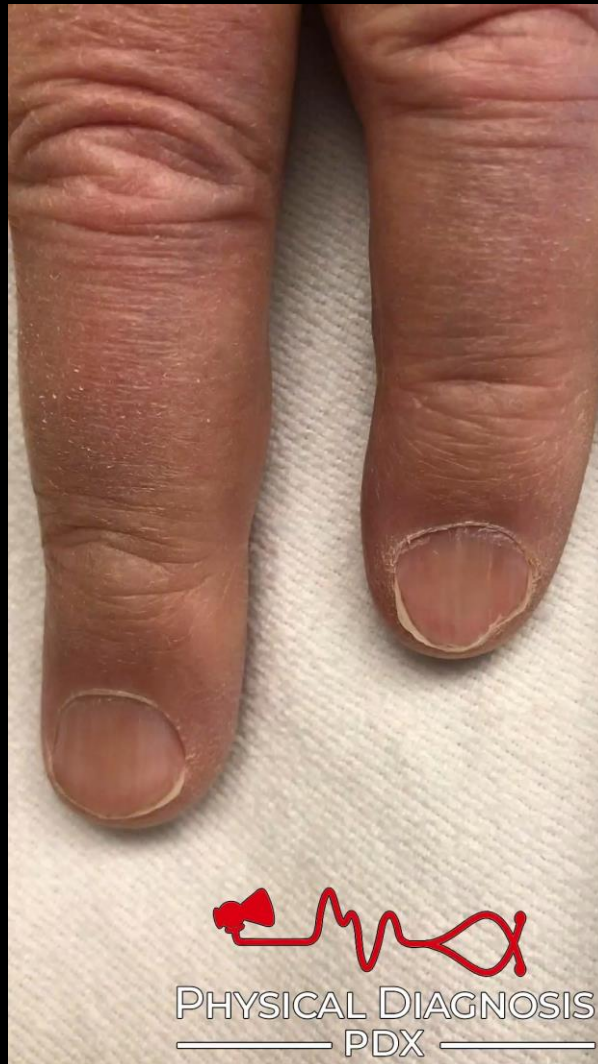Case #10: 62 y/o man with heart failure

T 36.8, HR 84, BP 177/56 mm Hg, RR 16

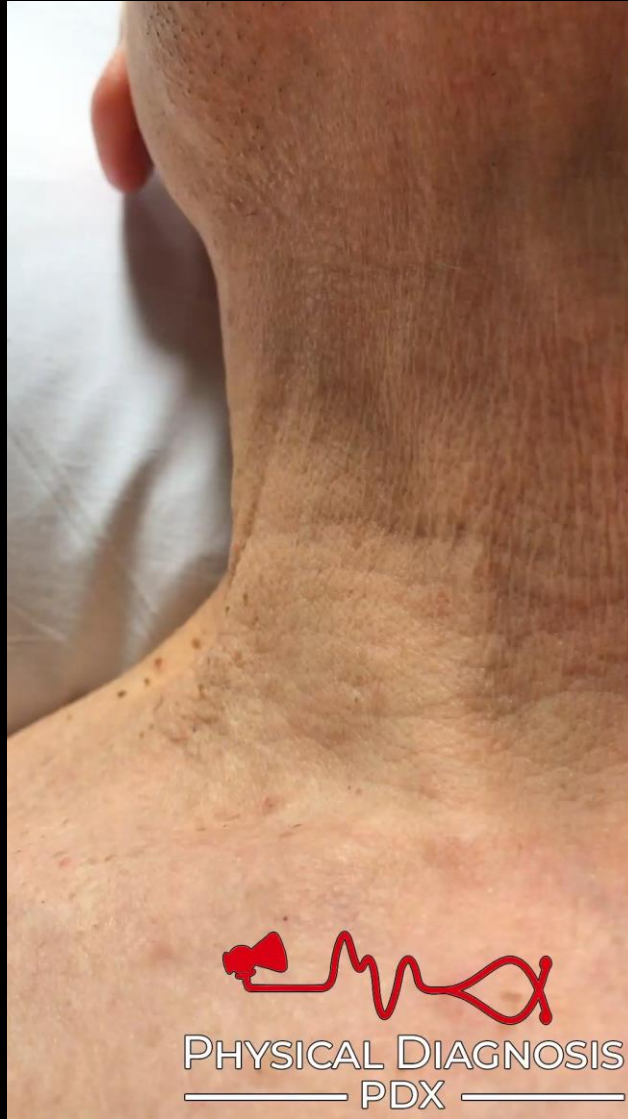Case #10: 62 y/o man with heart failure

T 36.8, HR 84, BP 177/56 mm Hg, RR 16

Case #10: 62 y/o man with heart failure



Case #10: 62 y/o man with heart failure



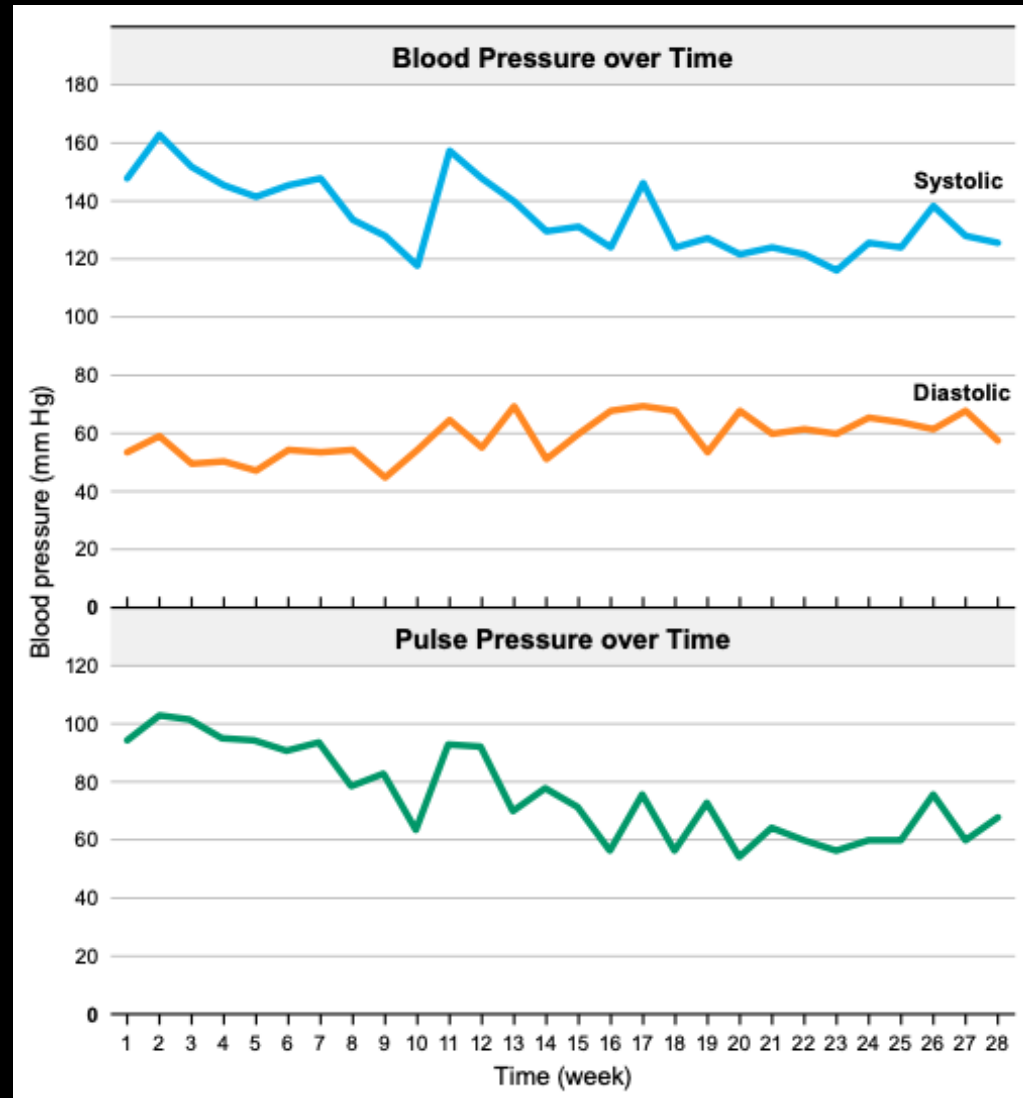
Case #10: 62 y/o man with heart failure

- Clinical findings:
 - Wide pulse pressure
 - Quincke's pulse
 - Bounding peripheral pulse
- **Underlying diagnosis: ?**

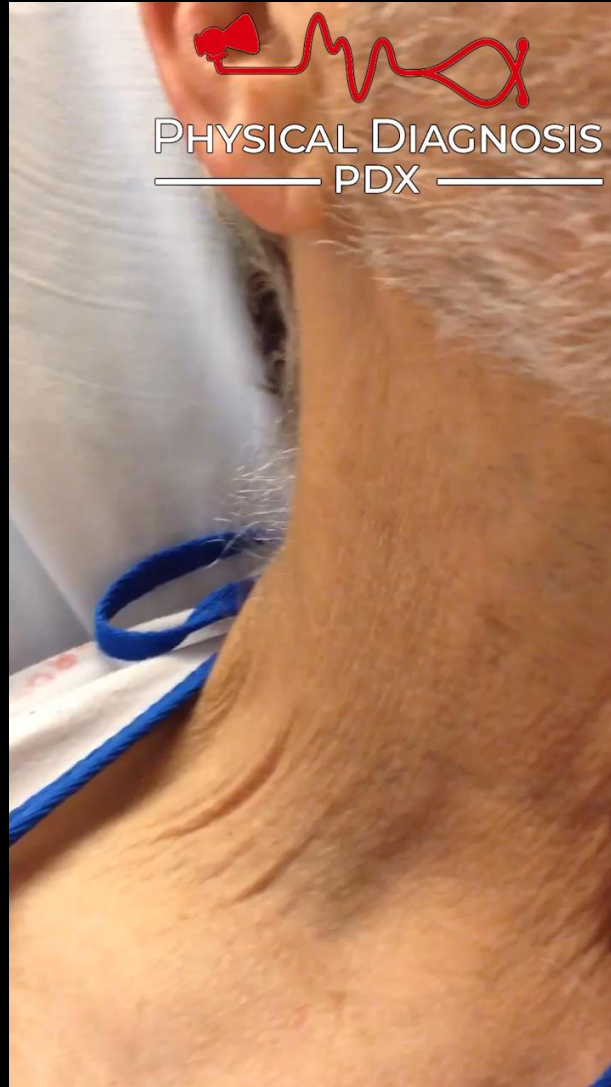Case #10: 62 y/o man with heart failure

- Clinical findings:
 - Wide pulse pressure
 - Quincke's pulse
 - Bounding peripheral pulse
- **Underlying diagnosis: Wet beriberi (thiamine deficiency)**

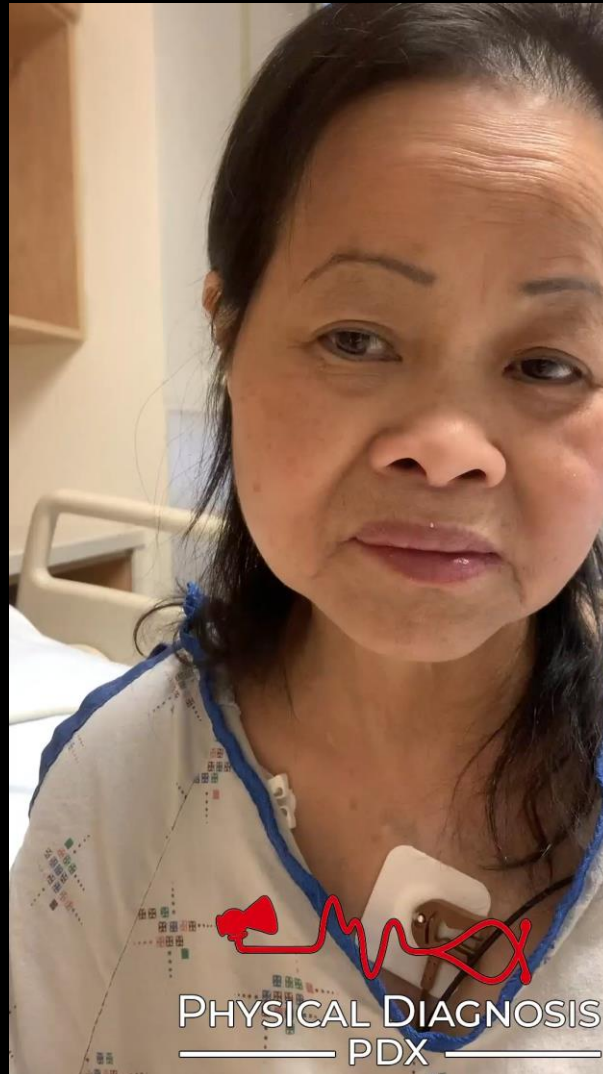Case #10: 62 y/o man with heart failure



Case #11: 60 y/o man w dyspnea



Case #11: 60 y/o man w dyspnea



PHYSICAL DIAGNOSIS
PDX

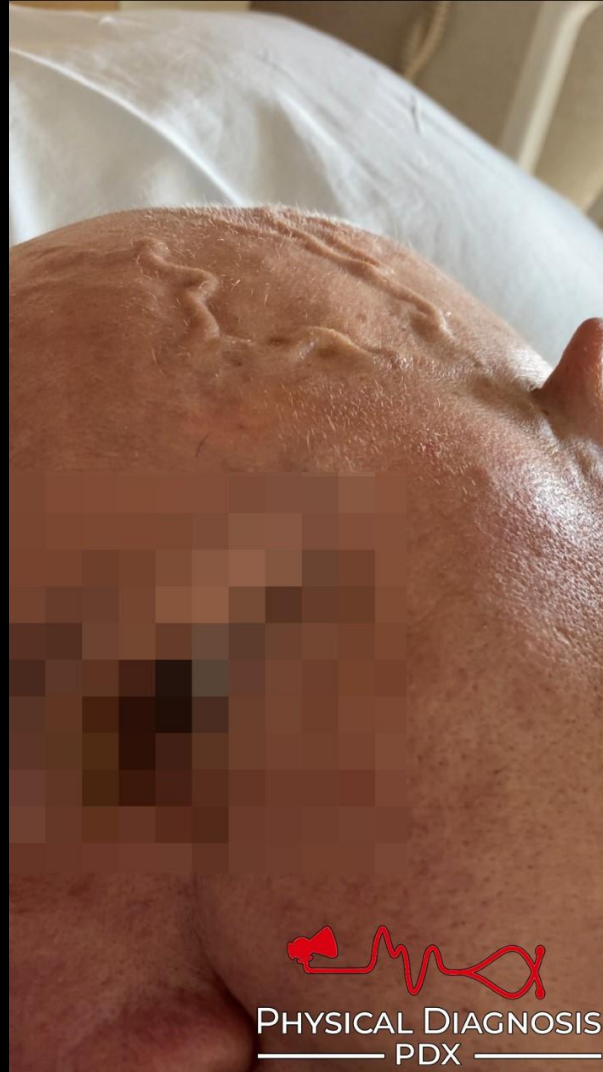Case #11: 60 y/o man w dyspnea

- Clinical findings:
 - Lancisi's sign (CV fusion wave)
 - Side-to-side head bob
- **Underlying diagnosis: ?**

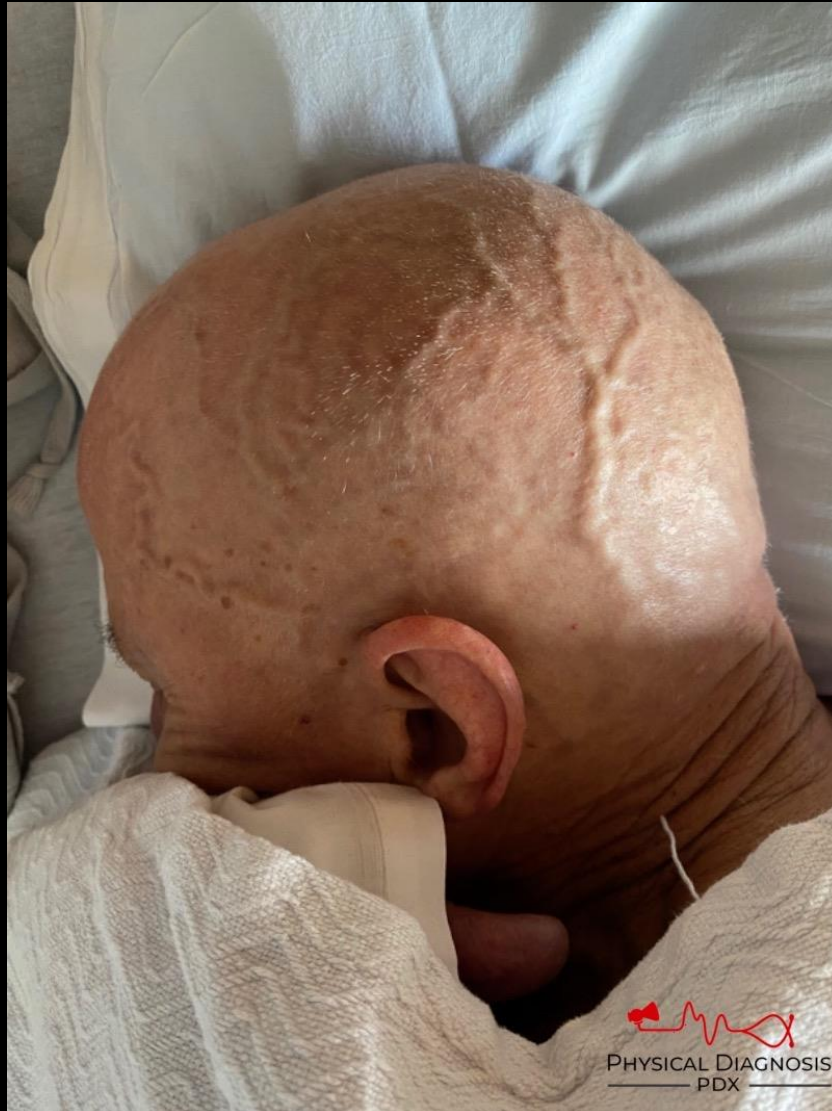Case #11: 60 y/o man w dyspnea

- Clinical findings:
 - Lancisi's sign (CV fusion wave)
 - Side-to-side head bob
- **Underlying diagnosis: Tricuspid valve regurgitation**

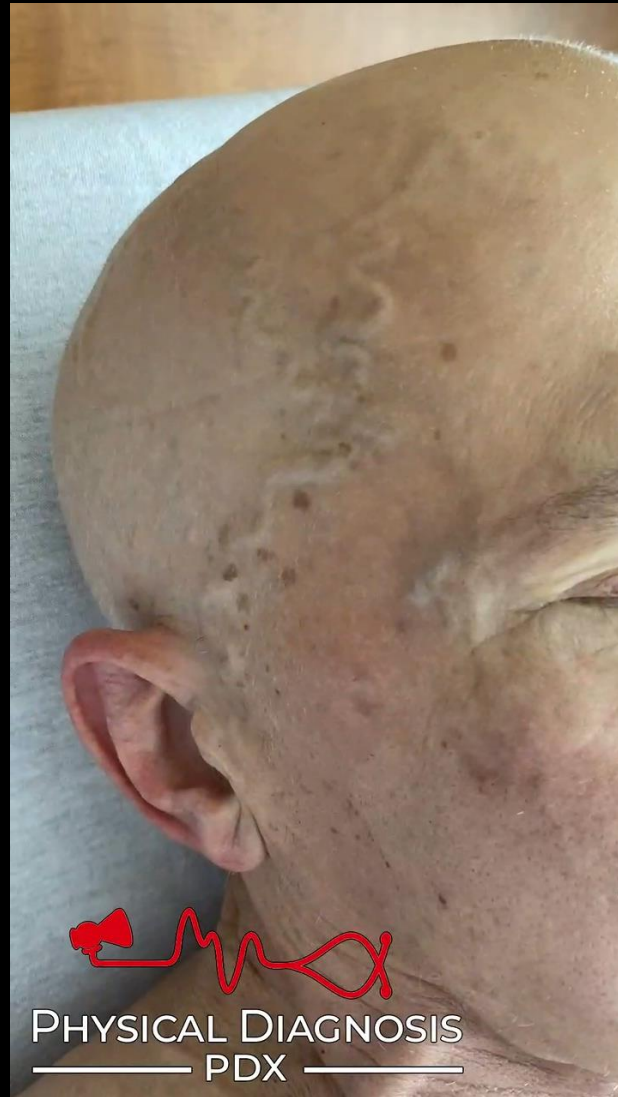Case #12: 55 y/o man w ascites



Case #12: 55 y/o man w ascites



Case #12: 55 y/o man w ascites



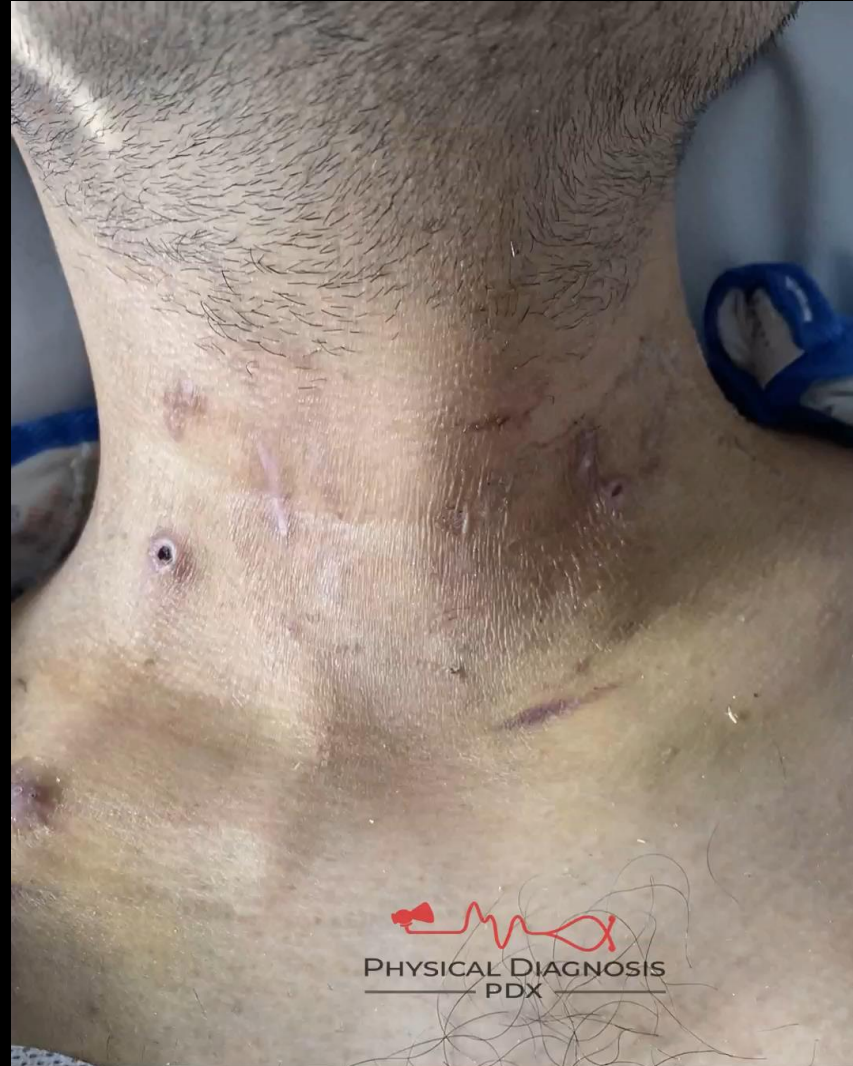Case #12: 55 y/o man w ascites

- Clinical findings:
 - Dilated head veins
- **Underlying diagnosis: ?**

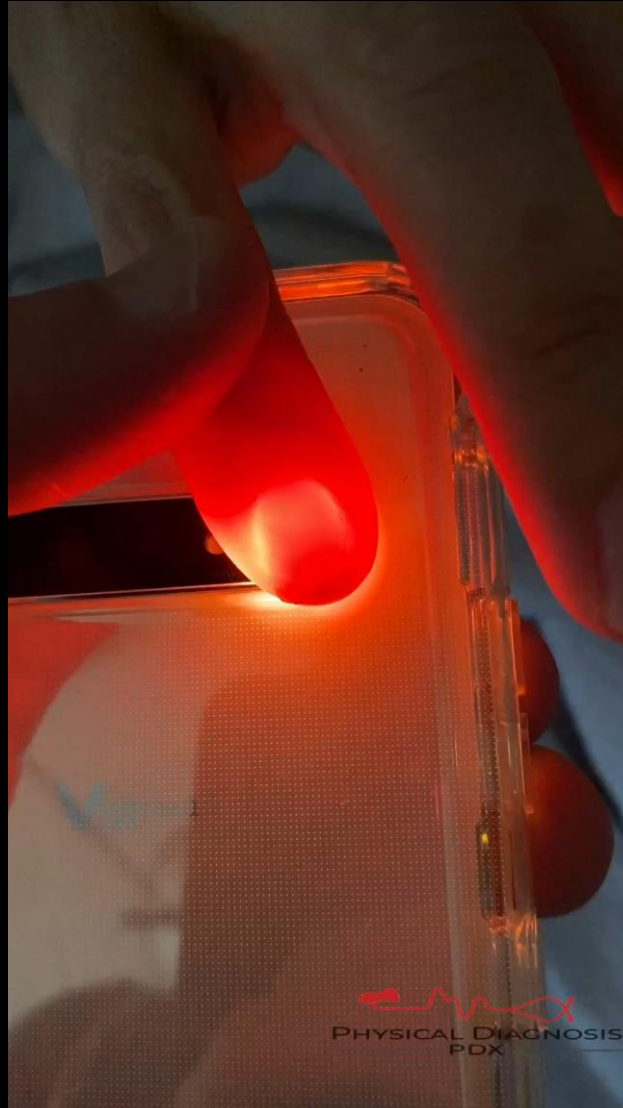Case #12: 55 y/o man w ascites

- Clinical findings:
 - Dilated head veins
- **Underlying diagnosis: Heart failure**

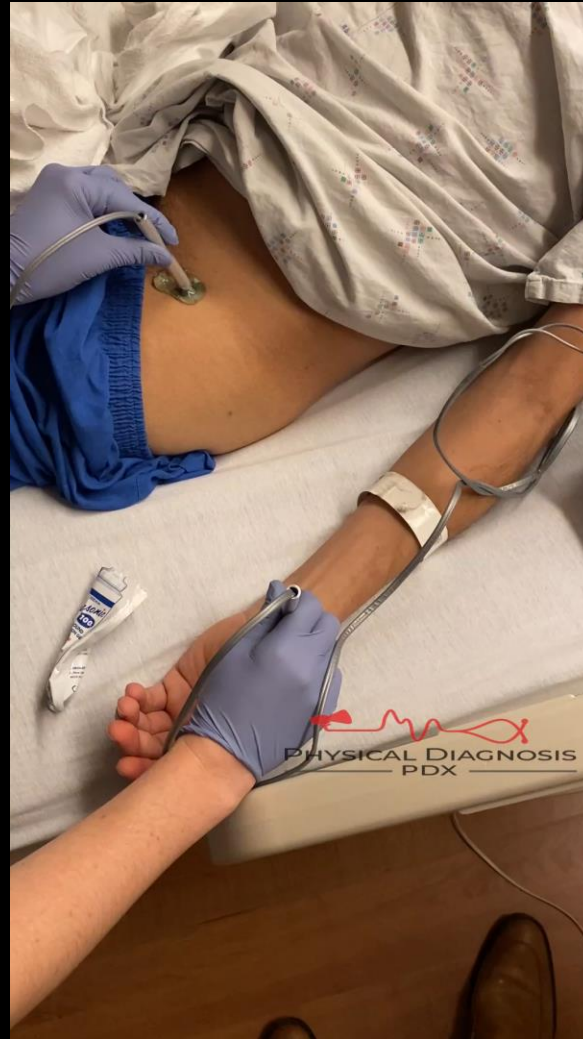Case #13: 44 y/o man w heart failure



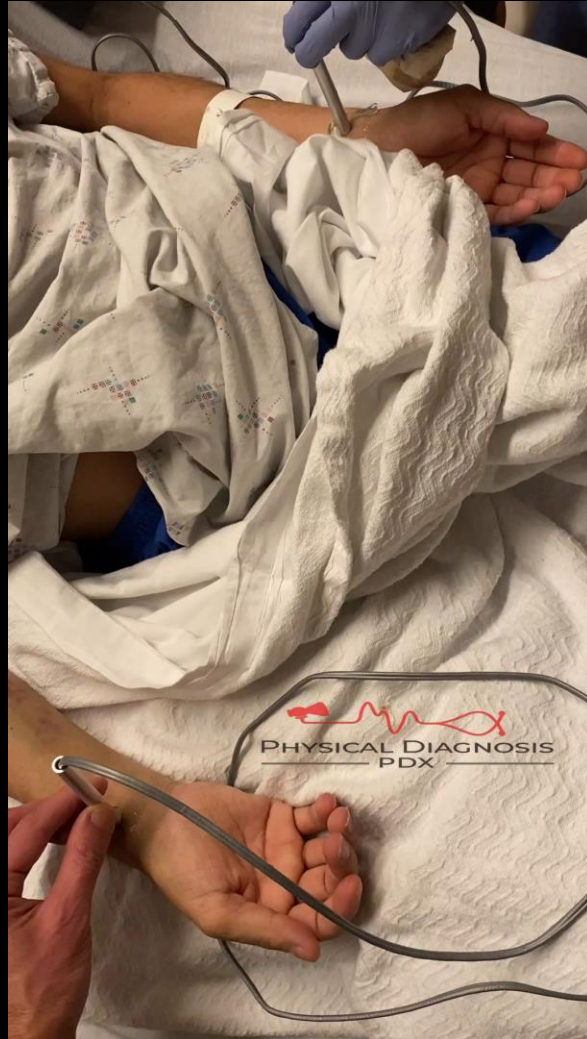Case #13: 44 y/o man w heart failure



Case #13: 44 y/o man w heart failure



Case #13: 44 y/o man w heart failure



Case #13: 44 y/o man w heart failure



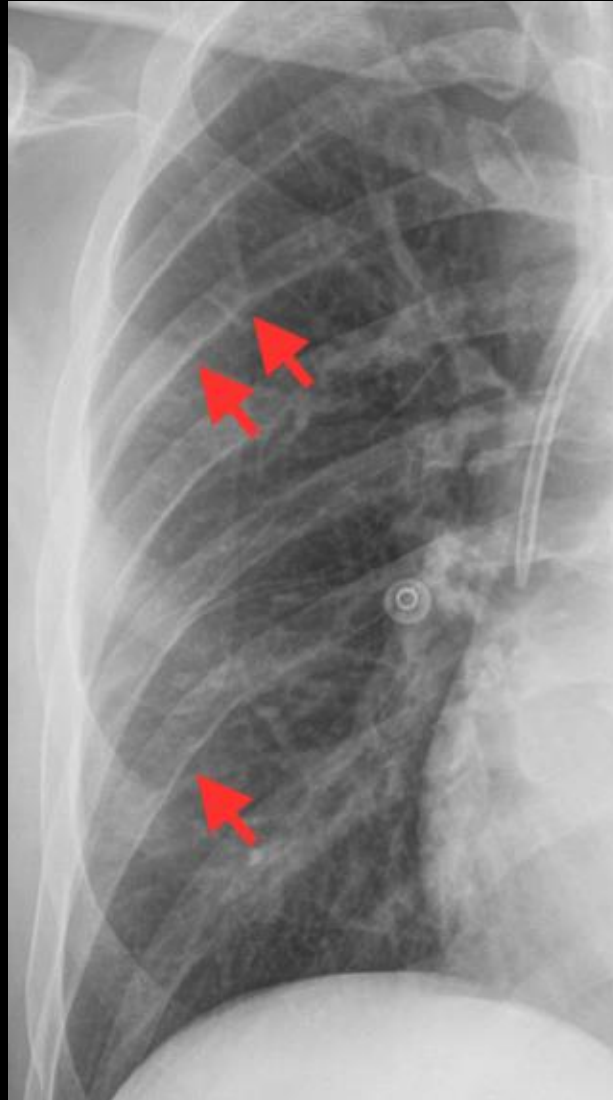
Case #13: 44 y/o man w heart failure

- Clinical findings:
 - Bounding carotid pulse
 - Quincke's pulse
 - Radial-femoral pulse delay
- **Underlying diagnosis: ?**

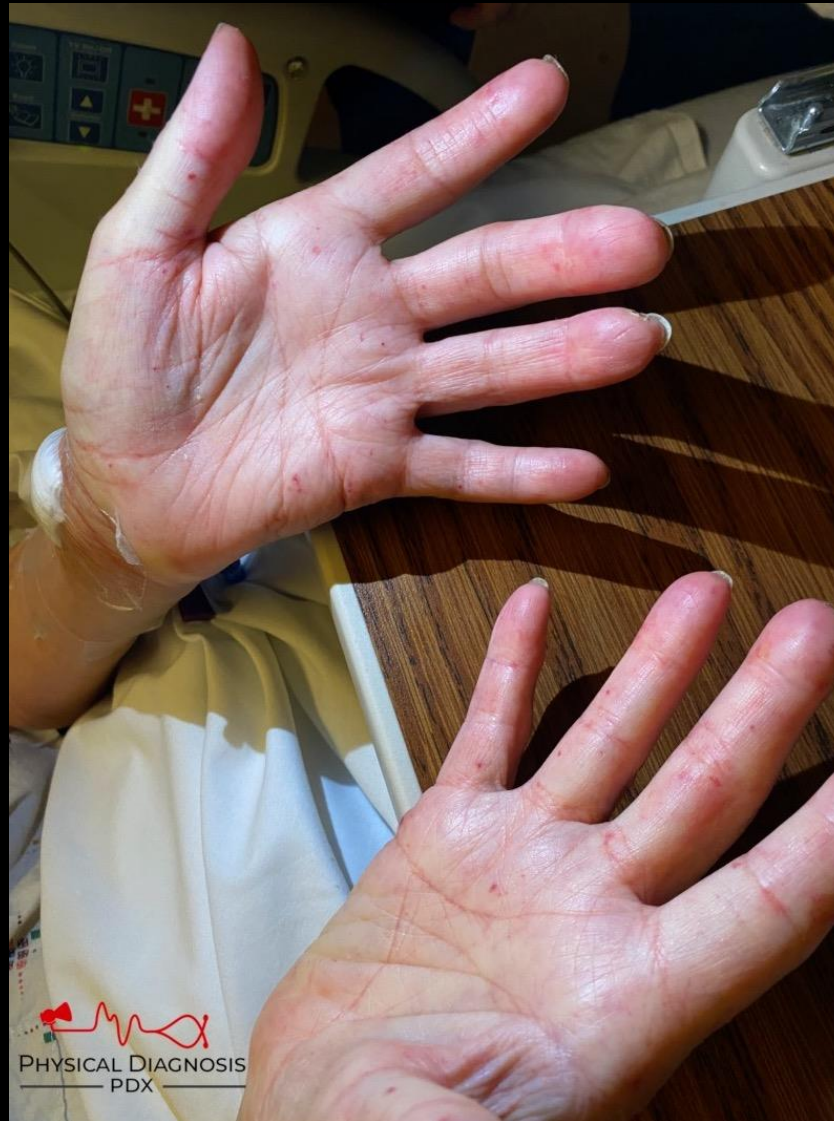Case #13: 44 y/o man w heart failure

- Clinical findings:
 - Bounding carotid pulse
 - Quincke's pulse
 - Radial-femoral pulse delay
- **Underlying diagnosis: Coarctation of the aorta**

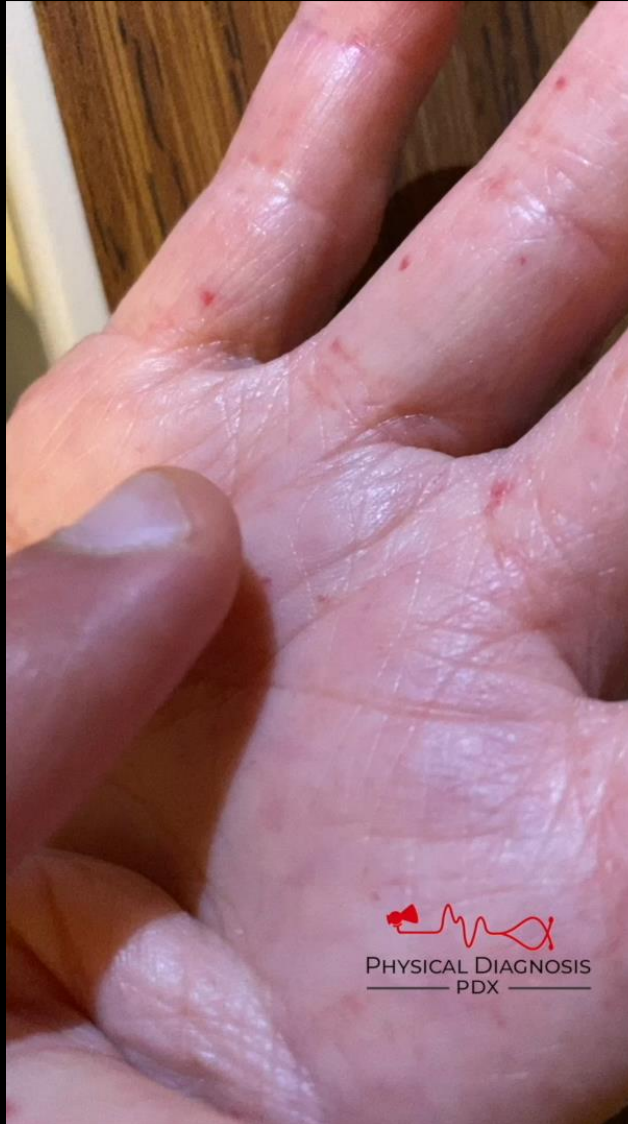Case #13: 44 y/o man w heart failure



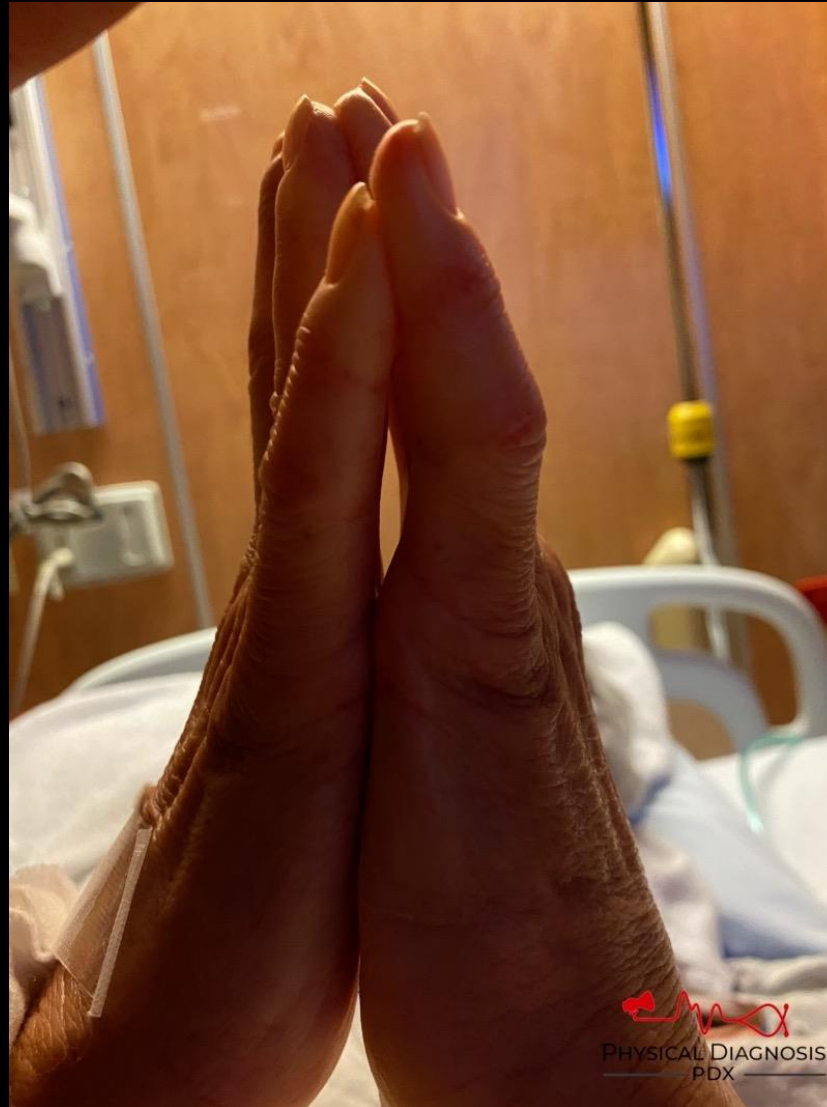Case #14: 46 y/o woman w dyspnea



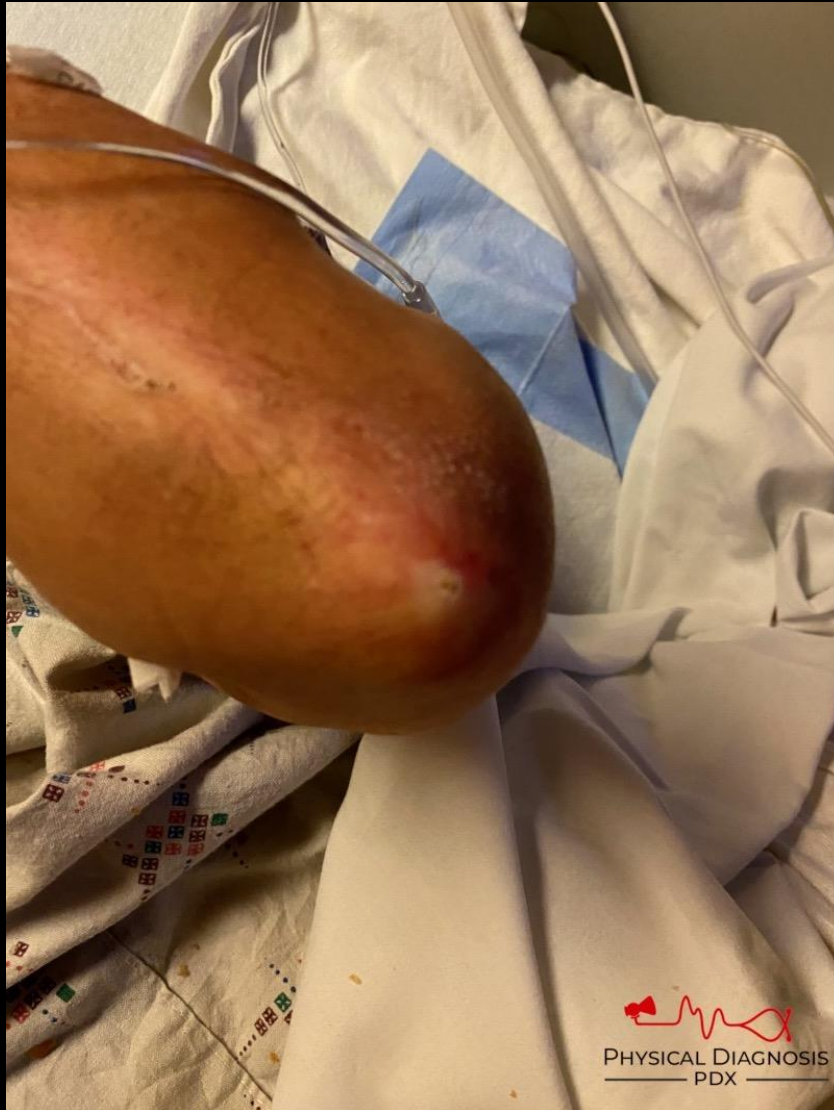Case #14: 46 y/o woman w dyspnea



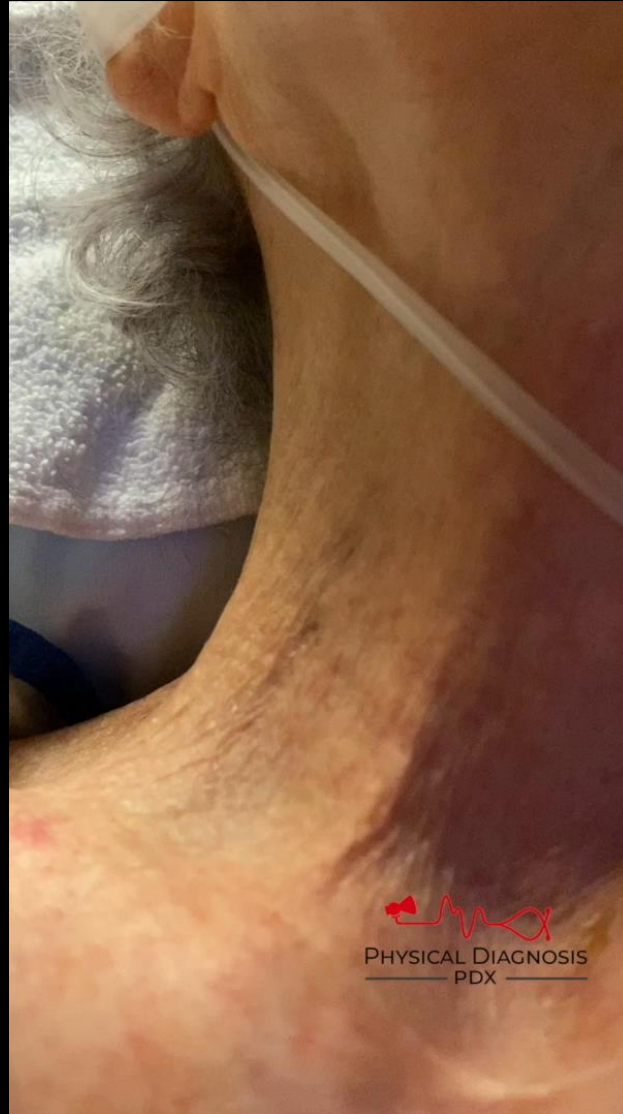Case #14: 46 y/o woman w dyspnea



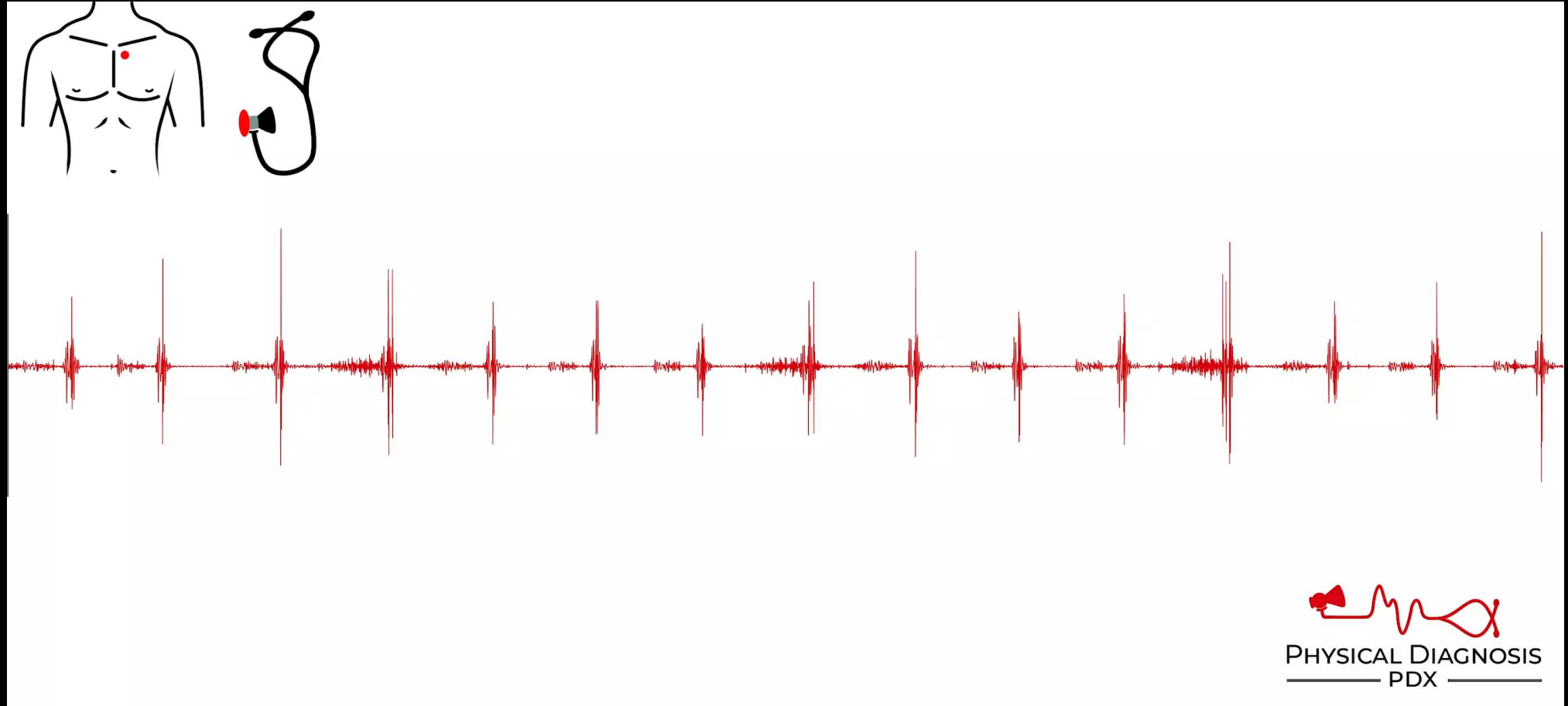
Case #14: 46 y/o woman w dyspnea



Case #14: 46 y/o woman w dyspnea



Case #14: 46 y/o woman w dyspnea



Case #14: 46 y/o woman w dyspnea

- Clinical findings:
 - Telangiectasias
 - Sclerodactyly (with prayer sign)
 - Calcinosis cutis
 - Kussmaul's sign
 - Loud P2
- **Underlying diagnosis: ?**

Case #14: 46 y/o woman w dyspnea

- Clinical findings:
 - Telangiectasias
 - Sclerodactyly (with prayer sign)
 - Calcinosis cutis
 - Kussmaul's sign
 - Loud P2
- Underlying diagnosis: **Systemic sclerosis w pulm HTN**

Case #15: 26 y/o woman w TIA

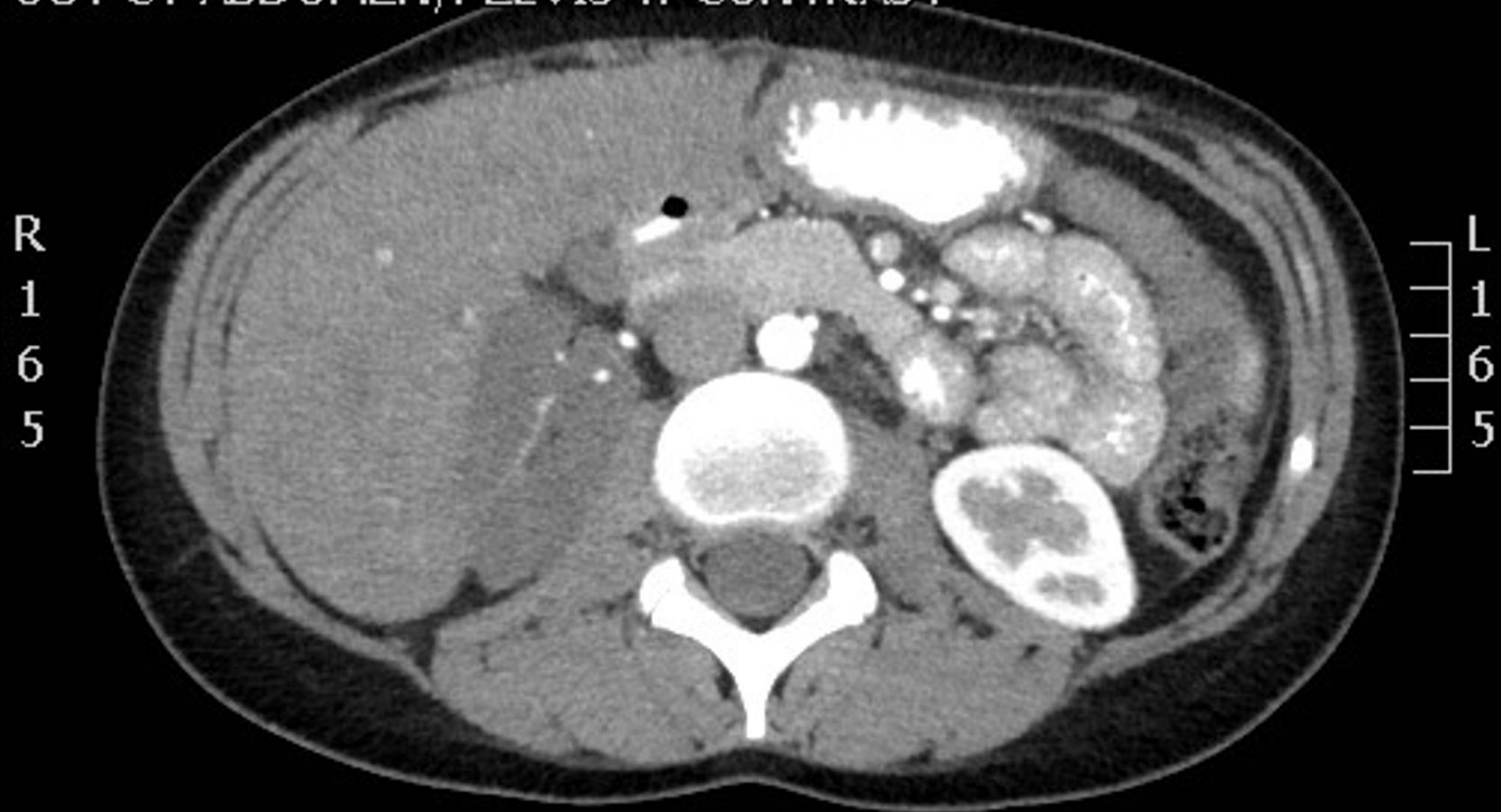- ED visit #1:
 - 5 minutes of right-sided weakness and dysarthria
 - Exam documented as normal
 - Discharged with PCP follow-up

Case #15: 26 y/o woman w TIA

- ED visit #2:
 - Acute right-sided flank pain
 - "Subtle murmur" documented in the exam section
 - CT abdomen obtained out of concern for appendicitis

Case #15: 26 y/o woman w TIA

OUT CT ABDOMEN/PELVIS W CONTRAST



Case #15: 26 y/o woman w TIA

- Admission (day #3)
 - Develops acute-onset hemoptysis and hypoxemia
 - Extensive workup for thrombophilia obtained
 - CTA chest obtained out of concern for pulmonary embolism

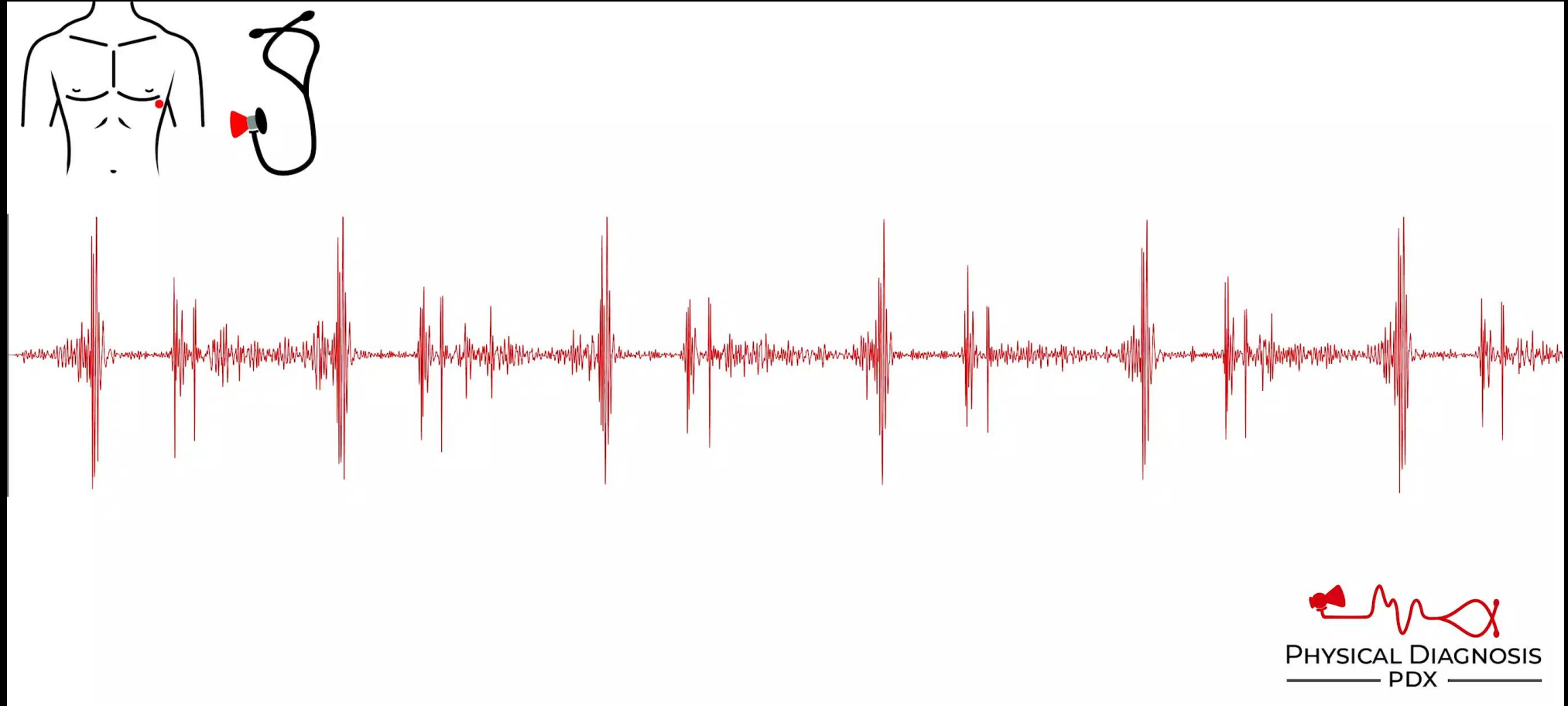
Case #15: 26 y/o woman w TIA

- Admission (day #3)
 - Develops acute-onset hemoptysis and hypoxemia
 - Extensive workup for thrombophilia obtained
 - CTA chest obtained out of concern for pulmonary embolism
 - Bronchoscopy performed

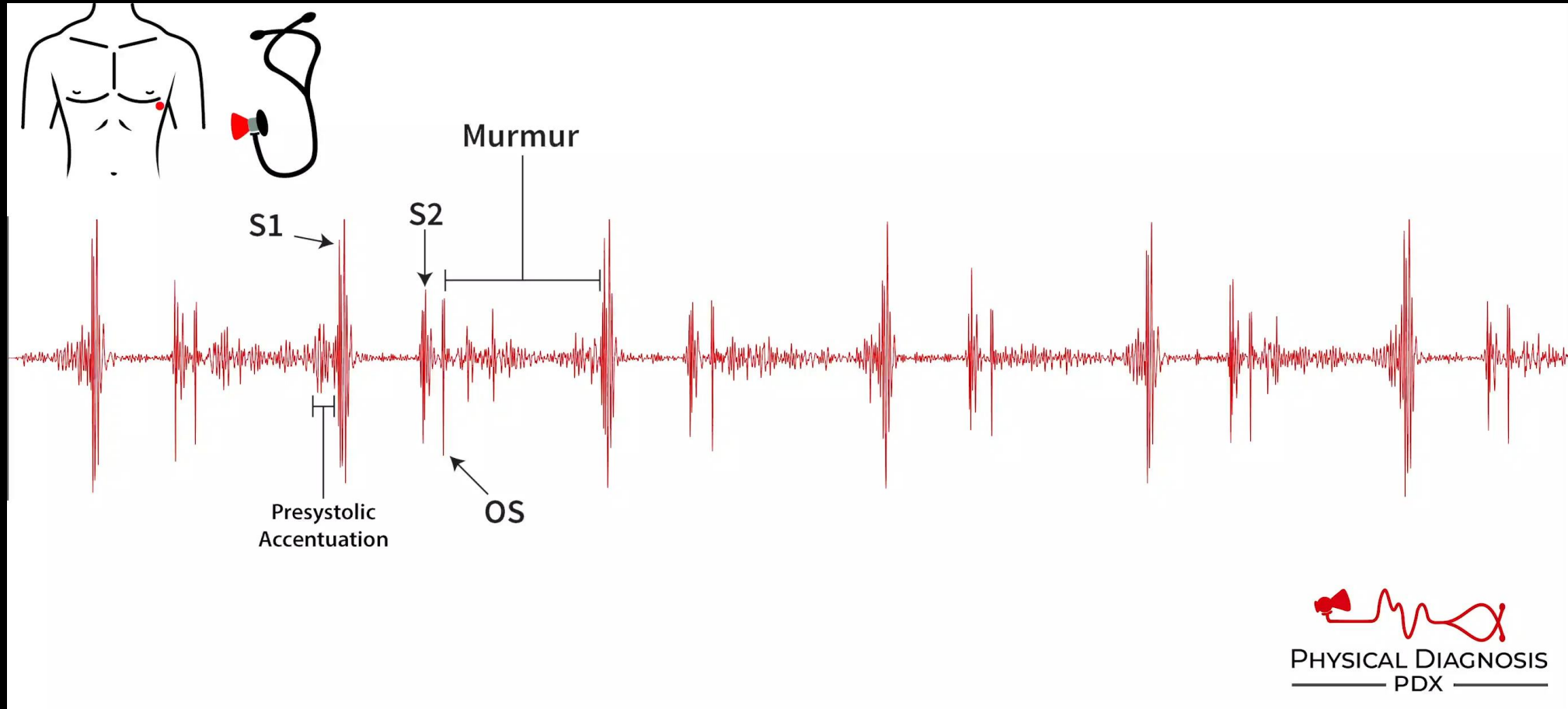
Case #15: 26 y/o woman w TIA

- Admission (day #3)
 - Develops acute-onset hemoptysis and hypoxemia
 - Extensive workup for thrombophilia obtained
 - CTA chest obtained out of concern for pulmonary embolism
 - Bronchoscopy performed
 - Echocardiography

Case #15: 26 y/o woman w TIA



Case #15: 26 y/o woman w TIA



Case #15: 26 y/o woman w TIA

- Clinical findings:
 - Loud S1
 - Opening snap
 - Rumbling diastolic murmur
- **Underlying diagnosis: ?**

Case #15: 26 y/o woman w TIA

- Clinical findings:
 - Loud S1
 - Opening snap
 - Rumbling diastolic murmur
- **Underlying diagnosis: Mitral stenosis**

THANK YOU

Additional Resources

- For more:
 - Physical Diagnosis PDX (www.pdxpdx.com)
 - Email: mansooan@ohsu.edu